

Clinica-Medical Image

A Case Blog on Dengue; You Can Find it Everywhere

Ankita Deoli*

Department of Bioscience and Biotechnology, Banasthali Vidyapith, Jaipur, India

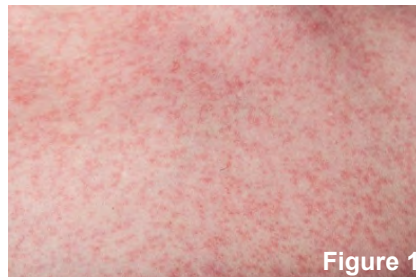

Figure 1: Macro of skin with rash from dengue disease.

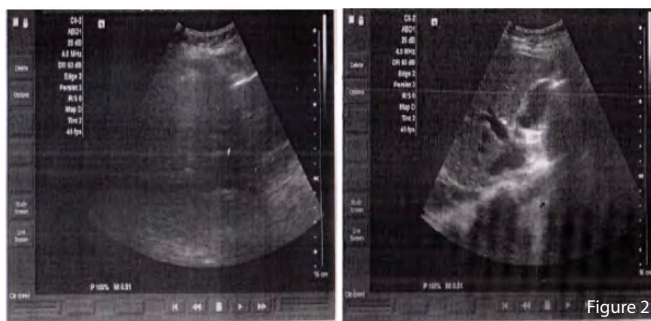


Figure 2: The walls of the gall bladder are edematous. Underlying lungs bases shows haziness.

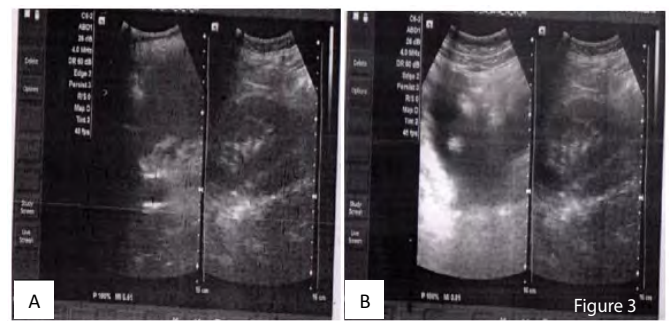


Figure 3: Evidence of free fluid seen in peritoneal cavity and pelvis (A); Evidence of fluid in pleural cavity (Right>Left) (B).

Case Blog

This case is of 23-year-old girl came for complaining of rash skin located on to the complete back and hands, severe joint and muscle pain, high fever (Figure 1). Also there is a mild pain in the liver and there is bleeding from the gums especially during brushing. After examination it is got to know that the patient is having the 20,000 platelets in her body as she is suffering from dengue. The patient is also having the frequent vomiting and abdominal pain. This work aims to describe the pattern found in the dermoscopic examination of patient affected by this condition, alerting to the possibility of their presence without any associated malignant condition.

A wide variety of symptoms are documented in the literature as the initial presentation of dengue. Sometimes it is hard to speculate dengue encephalitis by history, assessment, and initial investigations in the patient. This sort of atypical introduction of Dengue Fever can prompt demonstrative deferrals and adverse patient results.

The physical examination in dengue fever should be directed towards identifying warning signs that the patient has or may develop severe disease warranting in hospital observation and/or intensive treatment. These warning signs include Tachycardia, postural hypotension, a narrow pulse pressure (<20 mmHG), lethargy, restlessness, mucosal bleeding, Ascites, Abdominal tenderness and pedal edema.

Urine output: If the patient is not urinating at least every 6 hours, this may reflect intravascular volume depletion due to capillary leak, and the patient should be observed for the development of severe diseases.

Abdomen: Liver enlargement >2cm is a warning signs and the patient should be monitored for the development of severe disease.

During the Clinical observation (Screening) of the whole abdomen, result come up with information that the Liver is mildly enlarged in size,

*Corresponding author: Ankita Deoli, Department of Bioscience and Biotechnology, Banasthali Vidyapith, Jaipur, India, E-mail: deoli.ankita@gmail.com

Citation: Deoli A (2019) A Case Blog on Dengue; You Can Find it Everywhere. Int J Clin Med Imaging 7: 669.

Received: December 26, 2019; Accepted: January 07, 2020; Published: January 17, 2020

Copyright: © 2019 Deoli A. This is an open-access article distributed under the terms of the Creative Commons Attribution License, which permits unrestricted use, distribution, and reproduction in any medium, provided the original author and source are credited.

normal in shape and shows altered echotexture. No focal mass lesion is seen. And intrahepatic biliary radicles and vascular channels appear normal. It was observed that, Gall bladder not well distended and walls are edematous (Figures 2 and 3). Pancreas also normal in echotexture. Pancreatic duct is not dilated. Free fluid seen in peritoneal cavity and pelvis. Evidence of fluid in pleural cavity (Right>Left), also underlying lungs bases show haziness.

This case outlines the aspects of the epidemiology of dengue infections, the dengue virus and clinical features. Early diagnosis and treatment of this disease is of great importance in order to avoid the frequent fatal complications screening of the whole abdomen is also the standard for the diagnosis.

Keywords: Dengue; Abdomen screening; Edematous

Conflict of Interest

The author declares that there is no conflict of interest.

Patient Consent

Obtained.

Funding Sources

This research received no specific grant from any funding agency in the public, commercial, or not-for-profit sectors.