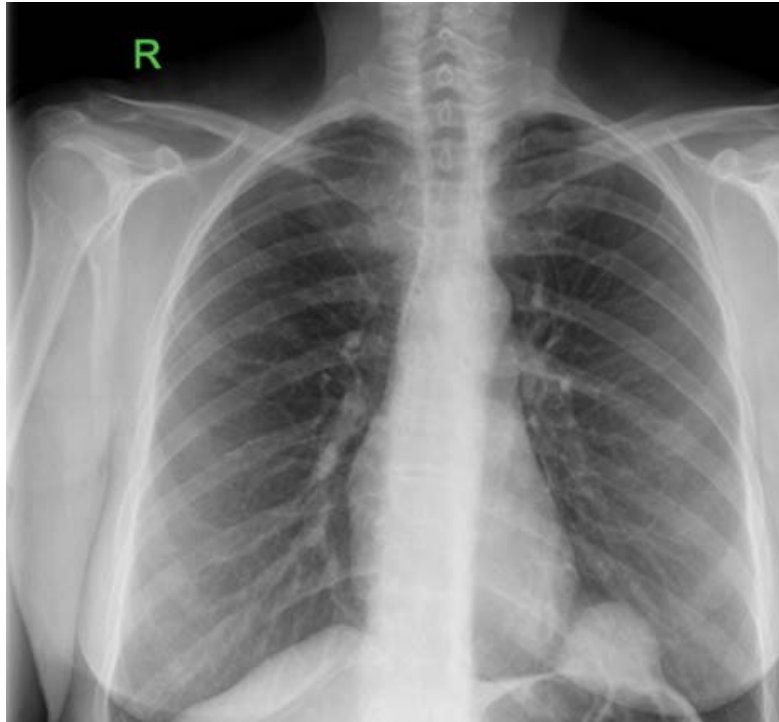


Case Blog

Title: A Dome on the Dome of the Hemidiaphragm

Deepali Prakash*

Department of Upper GI and Thoracics, Royal Devon and Exeter Hospital, UK



A 55 year old lady being evaluated for a right upper quadrant pain was found to have a dome shaped cystic mass on her chest X-ray. She had no other complaints, and had no significant past medical illness or surgical history. She had a normal ultrasound of her abdomen and was symptom-free following a dose of a proton pump inhibitor.

A CT thorax was requested for to characterize this strange incidental finding encountered on her chest X-ray. The lesion was radiologically diagnosed as a pericardial cyst, a rare congenital anomaly, often found on the right cardio-phrenic angle as an incidental finding.