

Clinical Image

A Pleural Catheter Malposition through Mediastinum to Contralateral Hemithorax: An Interesting Image

Fazli Yanik*

Department of Medicine, Trakya University, Edirne, Turkey

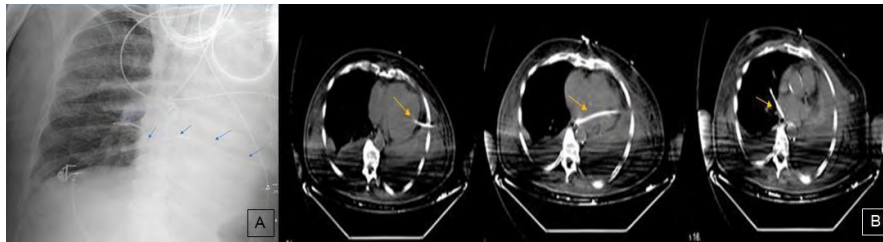


Figure 1: (A) Posteroanterior chest radiography shows pleural catheter malposition to contralateral hemithorax, marked with arrows. (B) Computed tomography shows tractus of pleural catheter through the whole mediastinum to the contralateral hemithorax, marked with arrows.

A 75 years-old male patient who have colon adenocarcinoma stayed in intensive care unit after colon resection and liver metastasectomy. Postoperative fifth day left pleural effusion detected. A pleural catheter (Pleuracan®) performed 5th intercostal space midaxillary line for pleural effusion. It was 1500 cc hemorrhagic drainage. Posteroanterior chest radiography showed pleural catheter malposition through across the mediastinum to the contralateral hemithorax (Figure 1A). Contrast enhanced axial computed tomography scan showed pleural catheter malposition across the left ventricle, whole mediastinum to the contralateral hemithorax (Figure 1B). He was treated conservatively. So the catheter pull out. Hemoglobin-hematocrit levels and vital parameters were followed up. They were not fall. After it pull out posteroanterior chest radiography showed that the lung was bilateral-expansion, no hematoma and no hemothorax.

The rate of chest tube malposition is less than 3% in cases hospitalized in the critical care unit or internal medicine service [1]. But pleural catheter malposition is extremely rare in the literature. If thoracic drains had not been inserted carefully and correctly, such malpositioning would have had much more serious consequences. So the catheter can easily injure relatively vulnerable tissue such as lung parenchyma, heart and other mediastinal structures. This case shows the importance of awareness of possible, rare, life-threatening complications during pleural catheter implantation [2,3].

References

1. Remerand F, Luce V, Badachi Y, Lu Q, Bouhemad B, et al. (2007) Incidence of chest tube malposition in the critically ill. *Anesthesiology* 106: 1112-1119.
2. Kirschbaum A, Damanakis A, Rolfes C, Bartsch D (2015) Endobronchial malposition of matthys pleural catheter: A case report. *Thorac Cardiovasc Surg Rep*. 4: 14-17.
3. Sahin KE, Alper I, Erozkhan Akan BA, Balcioğlu T (2015) Intrapleural placement of catheter and hemothorax during placement of Hickmann® catheter. *Journal of Dr.Behcet UZ Children's hospital* 5: 141-144.

*Corresponding author: Fazli Yanik, Department of Medicine, Trakya University, Edirne, Turkey, Tel: 054306523423; E-mail: fazliyanik@hotmail.com

Citation: Yanik F (2016) A Pleural Catheter Malposition through Mediastinum to Contralateral Hemithorax: An Interesting Image. *Int J Clin Med Imaging* 3: 519. doi:10.4172/2376-0249.1000519

Copyright: © 2016 Yanik F. This is an open-access article distributed under the terms of the Creative Commons Attribution License, which permits unrestricted use, distribution, and reproduction in any medium, provided the original author and source are credited.