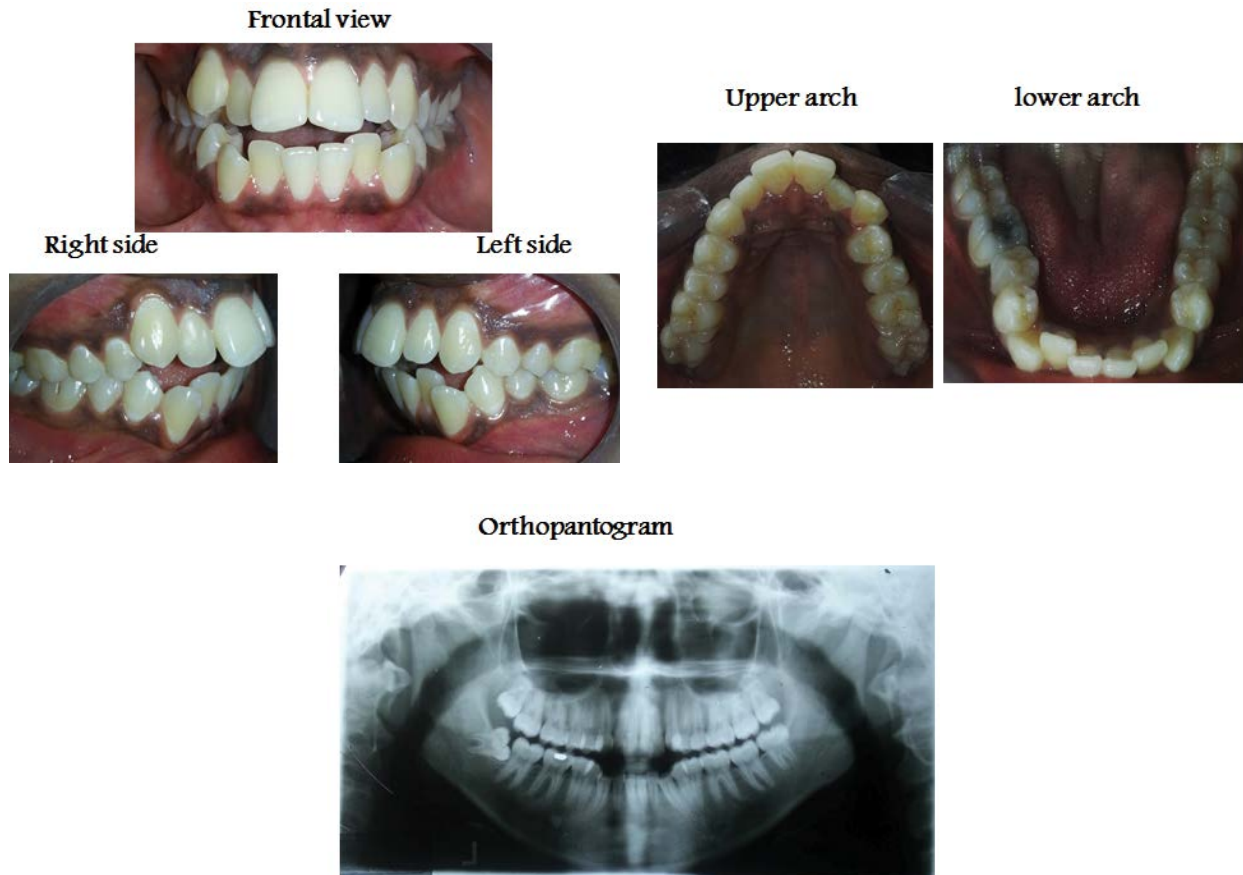


Medical Image

Title: Anterior Open Bite With Sever Crowding Upper and Lower Anterior Segments

Amal H. Abuaffan*

Department of Orthodontic, Pedodontics and Preventive Dentistry, University of Khartoum, Sudan



Sudanese female 32 years old complaining from difficulty in cutting the food. Intra oral view revealed, anterior open bite, canine to canine, with crowding upper and lower anterior segment.