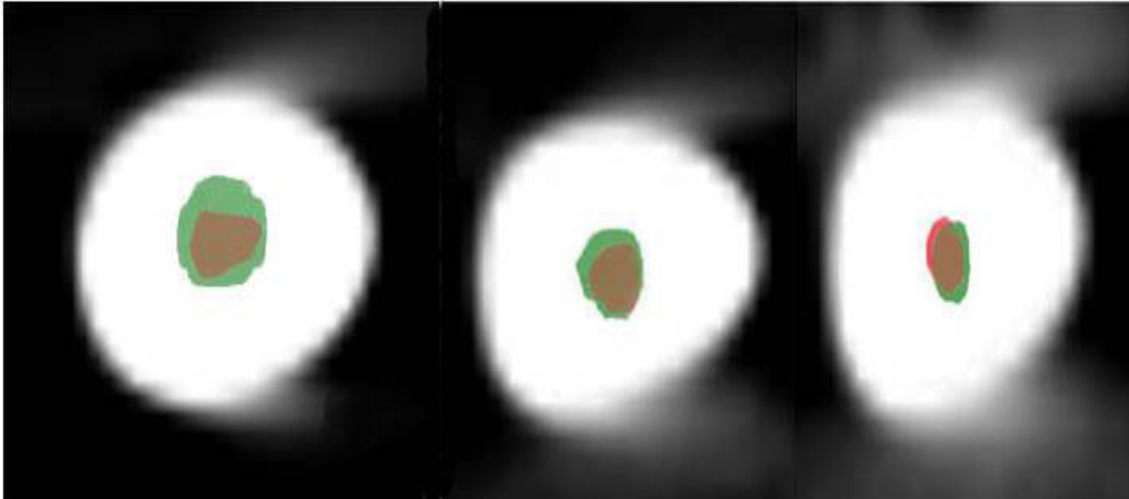


Clinical Image

Title: Axial Section of Cone Beam Computed Tomographic Analysis of Root Canal

Sawsan Taha Abuzeid

Department of Endodontics in King Abdulaziz Univeristy



The image showed the superimposition of pre- and post-operative images in axial section of cone beam computed tomographic analysis of root canal instrumented by Revo-S endodontic nickel titanium rotary system. The images determined few canal transportation and better centric ability at cervical (C), middle (M) and apical (A) regions. The isolated green colour (Post instrumented lumen) indicate the canal transportation, the isolated red colour (pre-instrumented lumen) indicated the area not touched by instruments, the brown color area indicates the overlapping pre- and post- operative lumen