

Clinica-Medical Image

Basal Cell Carcinoma of the Upper Palpebral Mucosa Simulating a Dermoscopically Melanoma

Selma Benkirane*, Mounia Bennani, Sara Elloudi, Hanane Bay-Bay and Fatima Zahra Mernissi

Department of Dermatology, University Hospital Hassan II, Morocco

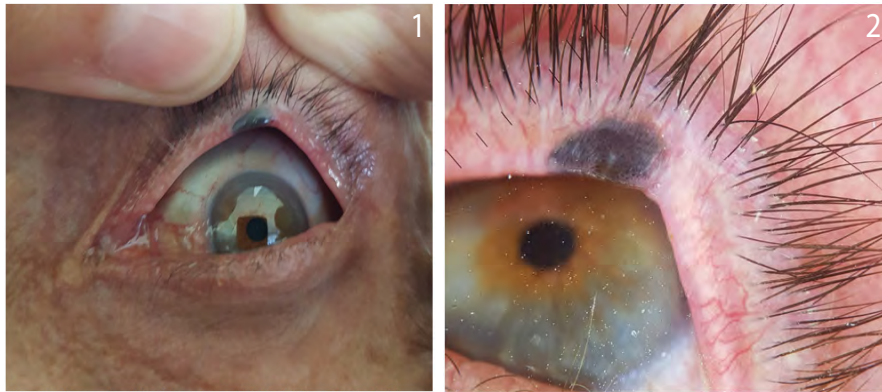


Figure 1: Pigmented nodule of about 1 cm well defined sitting at the level of the upper eyelid.

Figure 2: Dermoscopy showing the presence of a white blue veil and asymmetric pigmented globules.

Keywords

Cell carcinoma; Palpebral mucosa; Melanoma

Clinical Image

A patient aged 69, with antecedent of BCC of the nose, who has a palpebral tumor evolving for one year. Clinical examination reveals the presence of a pigmented nodule of about 1 cm at the level of the upper eyelid (Figure 1). Dermoscopy shows a white blue veil and asymmetric pigmented globules (Figure 2), these signs strongly indicate melanoma. The biopsy was in favor of a nodular pigmented BCC. The patient was referred to ophthalmology for complete excision.

The palpebral mucosa is an unusual site of BCC. This location is responsible for significant morbidity and may be life-threatening by invasion of the central nervous system. The lower eyelid location accounts for up to 2/3 of periocular basal cell carcinomas. We reported a case at the level of the upper eyelid and whose characteristics has been confused with melanoma showing a blue-white veil and asymmetric pigmented globules, whereas in pigmented BCC, we find the ovoid blue-gray nests, tree vessels, central ulceration, and whitish areas. In this case the histology made the diagnosis of BCC. Early diagnosis is important in order to improve the prognosis and avoid terebrant forms.

*Corresponding author: Selma Benkirane, Department of Dermatology, University Hospital Hassan II, Morocco, Tel: +212 5356-19053, E-mail: dr.benkiraneselma@gmail.com

Citation: Benkirane S, Bennani M, Elloudi S, Bay-Bay H, Mernissi FZ (2019) Basal Cell Carcinoma of the Upper Palpebral Mucosa Simulating a Dermoscopically Melanoma. *Int J Clin Med Imaging* 6: 655.

Copyright: © 2019 Benkirane S, et al. This is an open-access article distributed under the terms of the Creative Commons Attribution License, which permits unrestricted use, distribution, and reproduction in any medium, provided the original author and source are credited.