

Clinical-Medical Image

Clinical Signs of Locally Advanced Breast Cancer

Santhoshkumar Bandegudda

Basavatarakam Indo American Cancer Hospital and Research Institute, Hyderabad, India

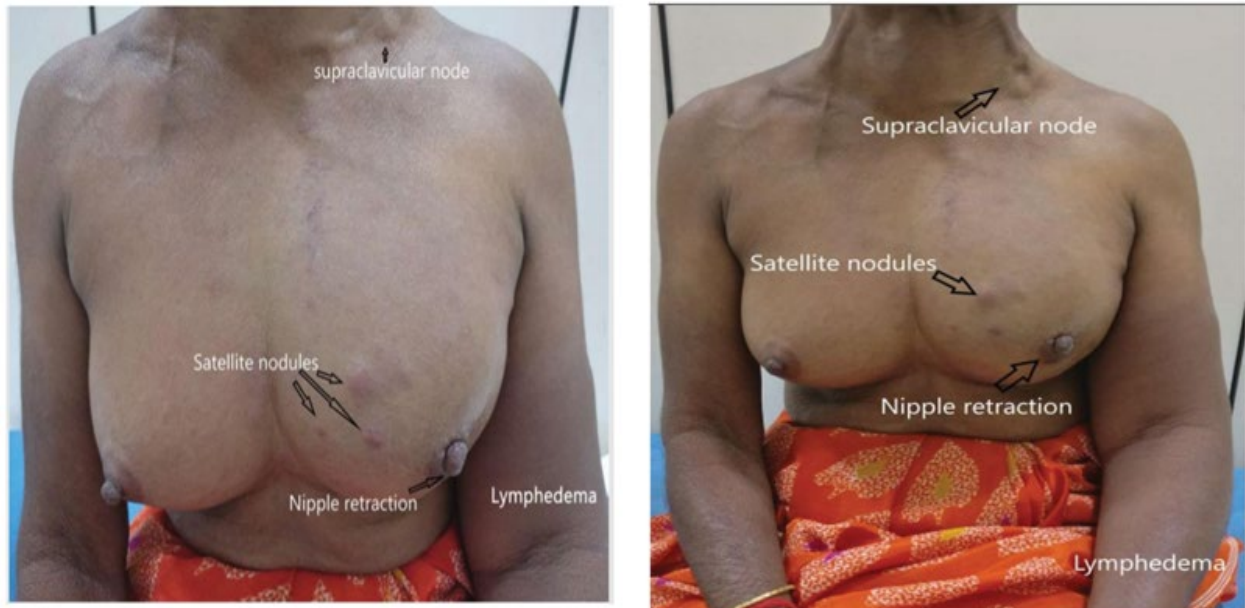


Figure 1: Clinical signs of locally advanced breast cancer in one single picture.

Clinical Image

We are reporting a case of 65-year female presented with swelling in left upper limb and lump in left breast for 1 year, on examination she had a 10 × 8 cm mass in the left breast with nipple retraction, satellite nodules, and an enlarged left supraclavicular node with left lymphedema. These photographs (Figure 1) here are unique as it depicts all clinical signs of locally advanced breast cancer in one single picture.

Keywords: Breast cancer; Lymphedema

Declaration of Interests

The authors declare that they have no competing interests.

*Corresponding author: Basavatarakam Indo American Cancer Hospital and Research Institute, Hyderabad, India, Tel: + 91-9968015569; E-mail: santupawarkims6820@gmail.com

Citation: Bandegudda S (2021) Clinical Signs of Locally Advanced Breast Cancer. *Int J Clin Med Imaging* 8:764.

Copyright: © 2021 Bandegudda S. This is an open-access article distributed under the terms of the Creative Commons Attribution License, which permits unrestricted use, distribution, and reproduction in any medium, provided the original author and source are credited.