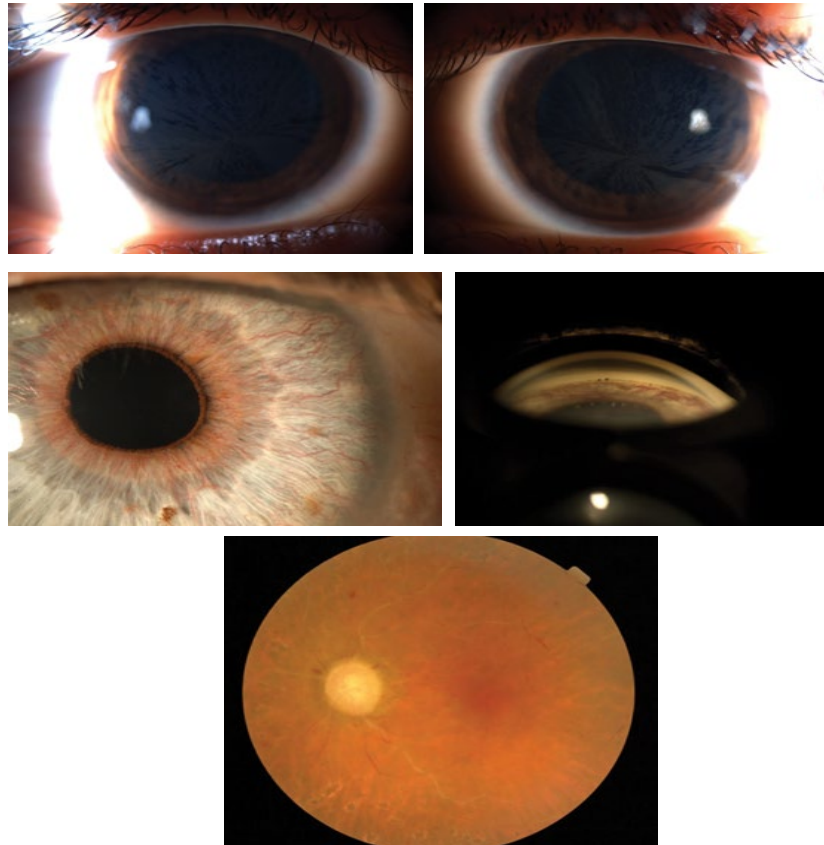


Clinical Image

Title: Cornea Verticillata and Obstruccion Carotid Artery

Melania Cigales^{1*}, Jairo Hoyos-Chacon¹ and Jairo E. Hoyos¹

Instituto Oftalmologico Hoyos, Barcelona, Spain



These photographs show cornea verticillata found during a routine eye exam in an 8-year-old girl, carrier of Fabry disease. Rubeosis iridis and retinal ischemia in a 70-year-old man due to a 70% obstruction in the left carotid artery

*Corresponding author: *Melania Cigales, Instituto Oftalmologico Hoyos, Barcelona, Spain, E-Mail: mcigalesj@gmail.com*

Copyright: © 2014 Cigales M. This is an open-access article distributed under the terms of the Creative Commons Attribution License, which permits unrestricted use, distribution, and reproduction in any medium, provided the original author and source are credited.