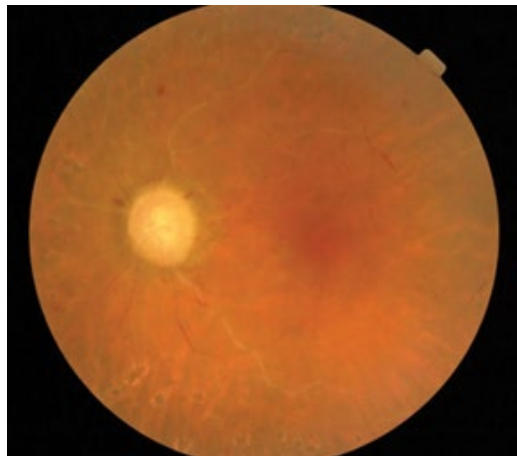
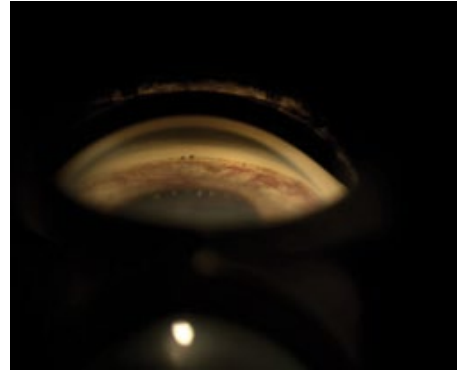
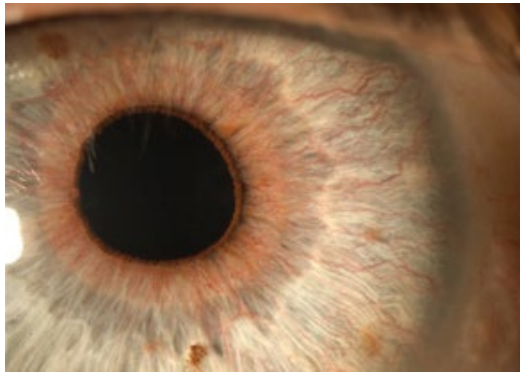


## Clinical Image

### **Title: Cornea Verticillata and Obstruccion Carotid Artery**

**Melania Cigales<sup>1\*</sup>, Jairo Hoyos-Chacon<sup>1</sup> and Jairo E. Hoyos<sup>1</sup>**

*Instituto Oftalmologico Hoyos, Barcelona, Spain*



Rubeosis iridis and retinal ischemia in a 70-year-old man due to a 70% obstruction in the left carotid artery

\*Corresponding author: *Melania Cigales, Instituto Oftalmologico Hoyos, Barcelona, Spain, E-Mail: [mcigalesj@gmail.com](mailto:mcigalesj@gmail.com)*

**Copyright:** © 2014 Cigales M. This is an open-access article distributed under the terms of the Creative Commons Attribution License, which permits unrestricted use, distribution, and reproduction in any medium, provided the original author and source are credited.