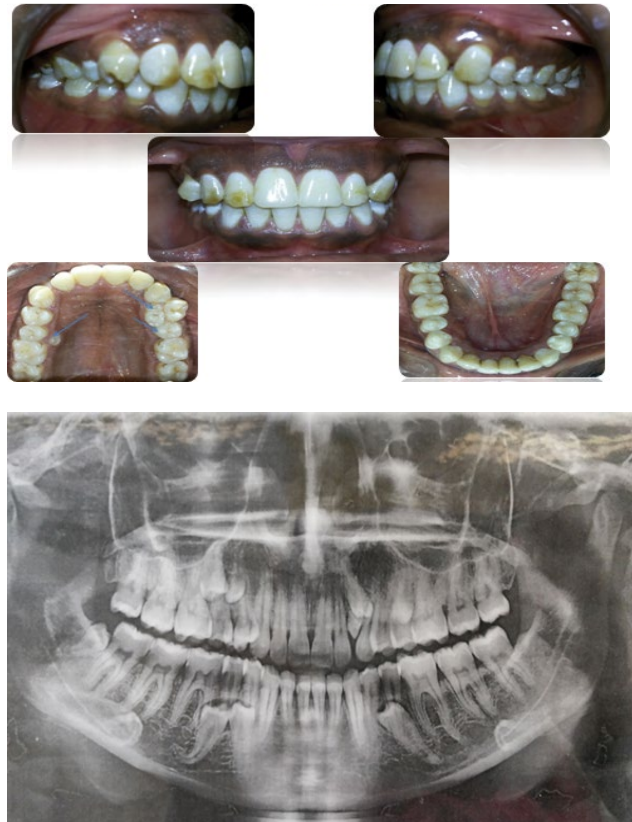


Title: Dental Fluorosis with Numerous Erupted and Un-Erupted Supernummary Teeth in Maxilla and Mandible

Amal H. Abuaffan*

Department of Orthodontic, Pedodontics and Preventive Dentistry, University of Khartoum, Sudan



Intra oral and Orthopantogram views for male 42 years old.

Dental fluorosis in the upper and lower teeth.

Multiple erupted and Un-erupted supernummary teeth in the maxilla: Numbers of erupted supernummary teeth was 3 and 5 impacted supernummary teeth. In the mandible: Impacted 4 supernummary teeth.

*Corresponding author: Amal H. Abuaffan, Department of Orthodontic, Pedodontics and Preventive Dentistry, University of Khartoum, Sudan, Tel: 00249912696035; E-mail: amalabuaffan@yahoo.com

Copyright: © 2015 Abuaffan AH. This is an open-access article distributed under the terms of the Creative Commons Attribution License, which permits unrestricted use, distribution, and reproduction in any medium, provided the original author and source are credited.