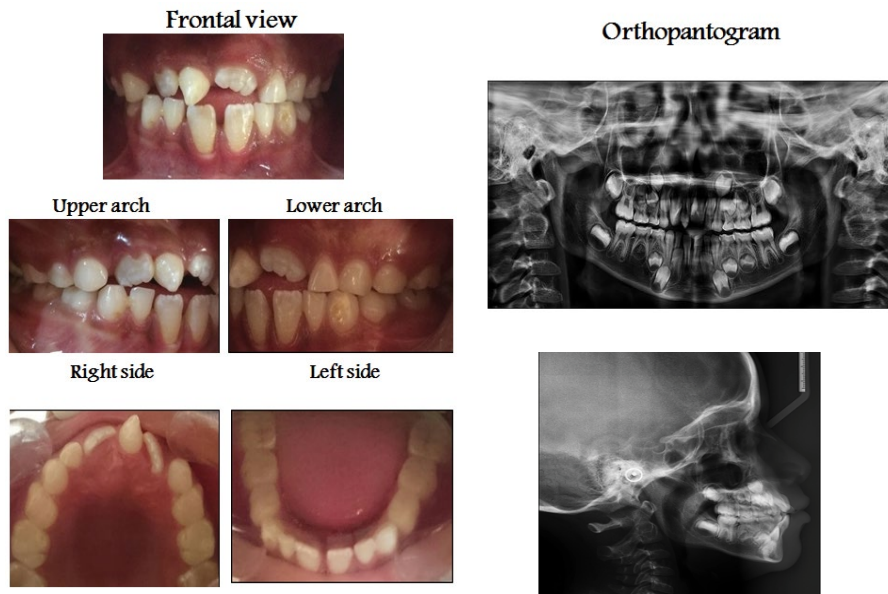


## Medical Image

### Title: Erupted Mesiodens Tooth between Upper Central Permanent Incisors

Amal H. Abuaffan\*

Department of Orthodontic, Pedodontics and Preventive Dentistry, University of Khartoum, Sudan



Sudanese boy in mixed dentition stage presented with erupted supernumerary teeth between the upper permanent central incisors.