

Clinica-Medical Image

## Erythema Papuloerosive of Sevestre and Jacquet: A Severe Diaper Dermatitis

Khadija Issoual\*, Achehboune K, Dahhouki S, Elloudi S, Bay Bay H, Mernissi FZ

Department of Dermatology, University Hospital Hassan II, Morocco

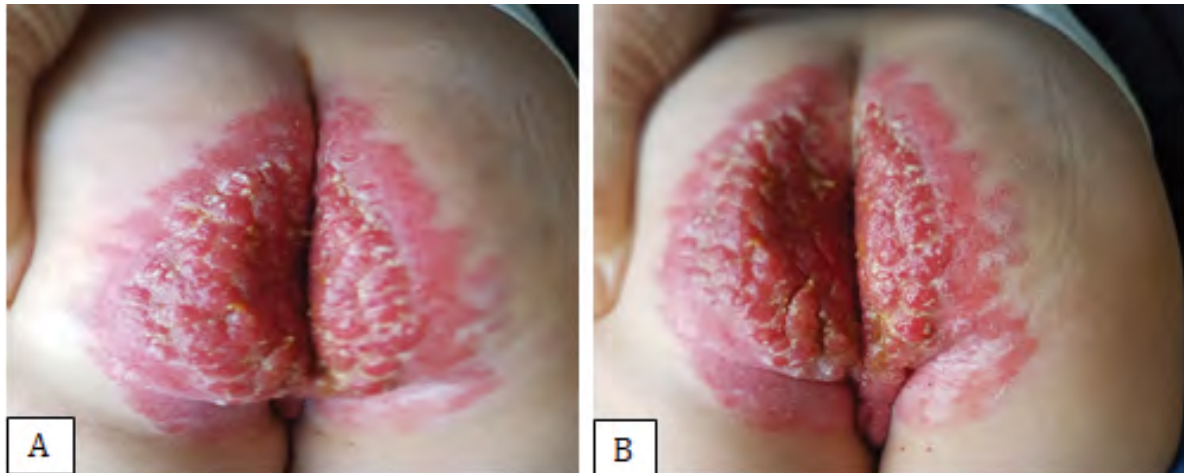


Figure 1: Symmetrical gluteal erythema, with numerous erythematous and Erosive papules and vegetations (as shown in A and B).

### Clinical Image

Erythema papuloerosive of Sevestre and Jacquet is a rare severe irritative dermatitis; it is often associated with urinary or fecal incontinence and poses a real therapeutic problem. This is a case in a 3 year old child. A 3-year-old infant diagnosed with Hirschsprung's disease from the age of 3 months; he benefited from a total colectomy and an ileo-anal anastomosis. Since then, the boy presented with chronic diarrhea, with an incontinence of the anal sphincter, followed by the appearance of skin lesions in the seat of progressive worsening, with repetitive superinfection. On clinical examination, it is a diffuse erythema, located symmetrically on the gluteal region, surmounted by several vivid erythematous papules and vegetations, erosive and bleeding, very painful and nauseous; resembling botriomycome like. We even did biopsy, which did not show malignant degeneration (Figure 1). Diagnosis was a severe form of Jacquet erosive diaper dermatitis or erythema papuloerosive of Sevestre and Jacquet.

**Keywords:** Erythema papuloerosive; Dermatitis; Hirschsprung's disease

---

\*Corresponding author: Khadija Issoual, Department of Dermatology, University Hospital Hassan II, Morocco, E-mail: khadijaissoual@gmail.com

Citation: Issoual K, Achehboune K, Dahhouki S, Elloudi S, Bay Bay H, et al. (2019) Erythema Papuloerosive of Sevestre and Jacquet: A Severe Diaper Dermatitis. *Int J Clin Med Imaging* 7: 668.

Copyright: © 2019 Issoual K, et al. This is an open-access article distributed under the terms of the Creative Commons Attribution License, which permits unrestricted use, distribution, and reproduction in any medium, provided the original author and source are credited.

---