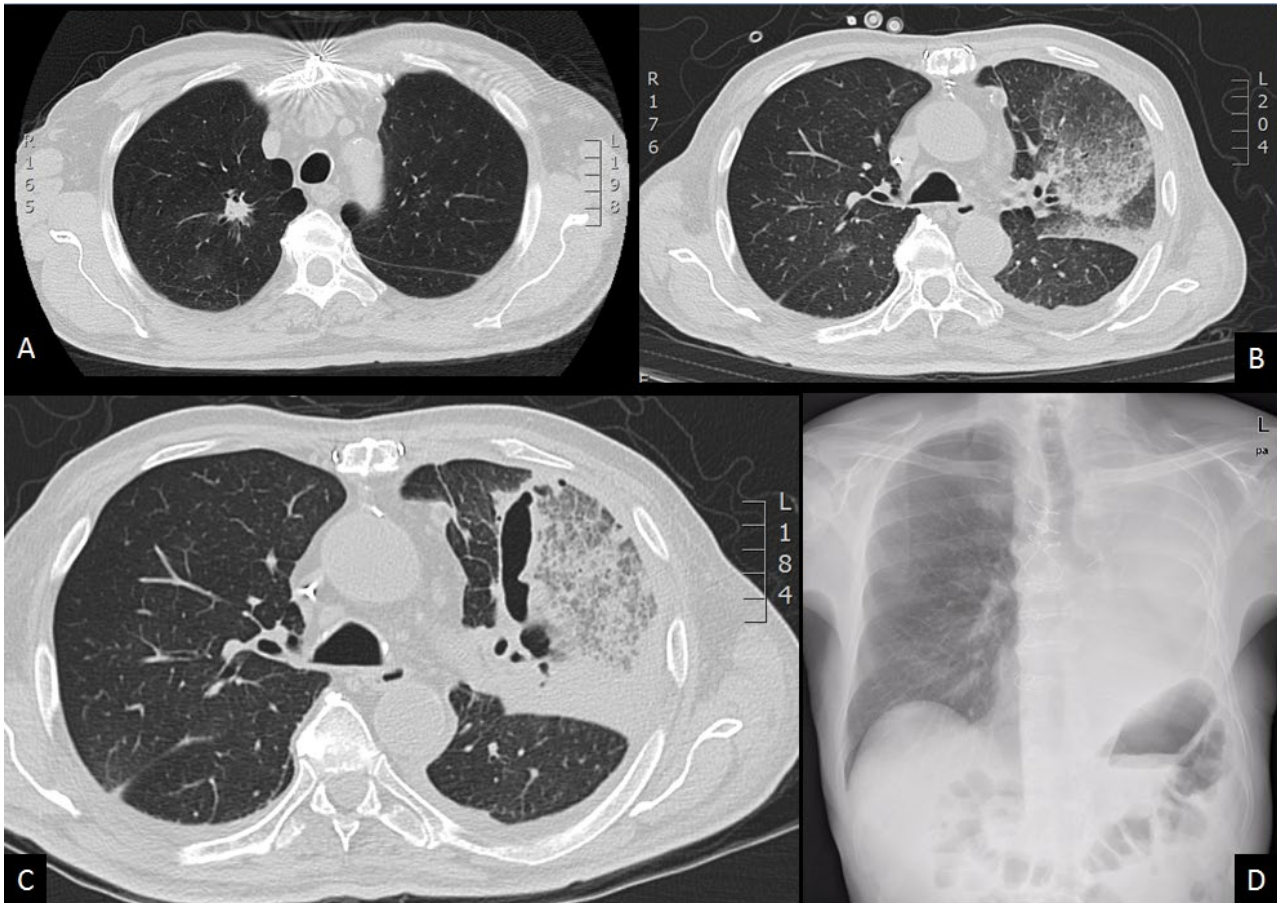


Clinical Image

Title: Evolution of Invasive Aspergillosis in Hematopoietic Stem Cell Transplantation

Peccatori Jacopo^{1*}, Zuanelli Brambilla Corrado¹, Levati Giorgia¹, Greco Raffaella¹, Giglio Fabio¹, Morelli Mara¹, Assanelli Andrea¹ and Ciceri Fabio¹

Hematology and Bone Marrow Transplantation Unit, San Raffaele Scientific Institute, Milano, Italy



Abstract

Invasive aspergillosis is still a major complication of allogeneic Hematopoietic Stem Cell Transplantation (HSCT). We describe a case of extensive fungal pneumonia due to *Aspergillus* spp successfully treated with a combination of antifungal agents and surgery.

Keywords: Aspergillosis; HSCT; Pneumonectomy

In November 2012, a 66-year-old caucasian male underwent an un-manipulated Hematopoietic Stem Cell Transplantation (HSCT) from his haploidentical daughter for a secondary Acute Myeloid Leukemia (AML) in relapse. Because of a single pulmonary nodule (Figure 1A) present before transplant, the patient received Voriconazole as secondary prophylaxis through the transplant. During post-transplantation aplasia, he developed a severe pneumonia with respiratory distress requiring non invasive ventilation support. A chest CT scan (Figure 1B) showed a massive lobar pneumonia with ground glass opacity; a bronchoalveolar lavage was diagnostic for septate hyphae suggestive for *Aspergillus* and panfungal PCR-assay was concomitantly positive. The patient added liposomal Amphotericin B to Voriconazole; after few days neutrophils engrafted. First bone marrow evaluation

*Corresponding author: Peccatori Jacopo, Hematology and Bone Marrow Transplantation Unit, San Raffaele Scientific Institute, Milano, Italy, E-Mail: peccatori.jacopo@hsr.it

Copyright: © 2014 Jacopo P, et al. This is an open-access article distributed under the terms of the Creative Commons Attribution License, which permits unrestricted use, distribution, and reproduction in any medium, provided the original author and source are credited.

at 30 days from HSCT demonstrated a complete remission from AML. Clinical conditions slowly improved. A chest CT scan (Figure 1C) showed a consolidation with cavitation of the major lesion. The patient was discharged after two months of combination therapy, on Posaconazole. At six months from HSCT, in continuous AML complete remission, the patient was brought in the operating theatre for left pneumonectomy. The patient is actually alive, in complete remission, with no respiratory distress and normal pulse oximetry in room air, at 18 months from HSCT (Figure 1D).

Submit your next manuscript and get advantages of OMICS Group submissions


Unique features:

- User friendly/feasible website-translation of your paper to 50 world's leading languages
- Audio Version of published paper
- Digital articles to share and explore

Special features:

- 300 Open Access Journals
- 25,000 editorial team
- 21 days rapid review process
- Quality and quick editorial, review and publication processing
- Indexing at PubMed (partial), Scopus, EBSCO, Index Copernicus and Google Scholar etc
- Sharing Option: Social Networking Enabled
- Authors, Reviewers and Editors rewarded with online Scientific Credits
- Better discount for your subsequent articles

Submit your manuscript at: <http://www.omicsonline.org/submission>



*Corresponding author: Peccatori Jacopo, Hematology and Bone Marrow Transplantation Unit, San Raffaele Scientific Institute, Milano, Italy, E-Mail: peccatori.jacopo@hsr.it