

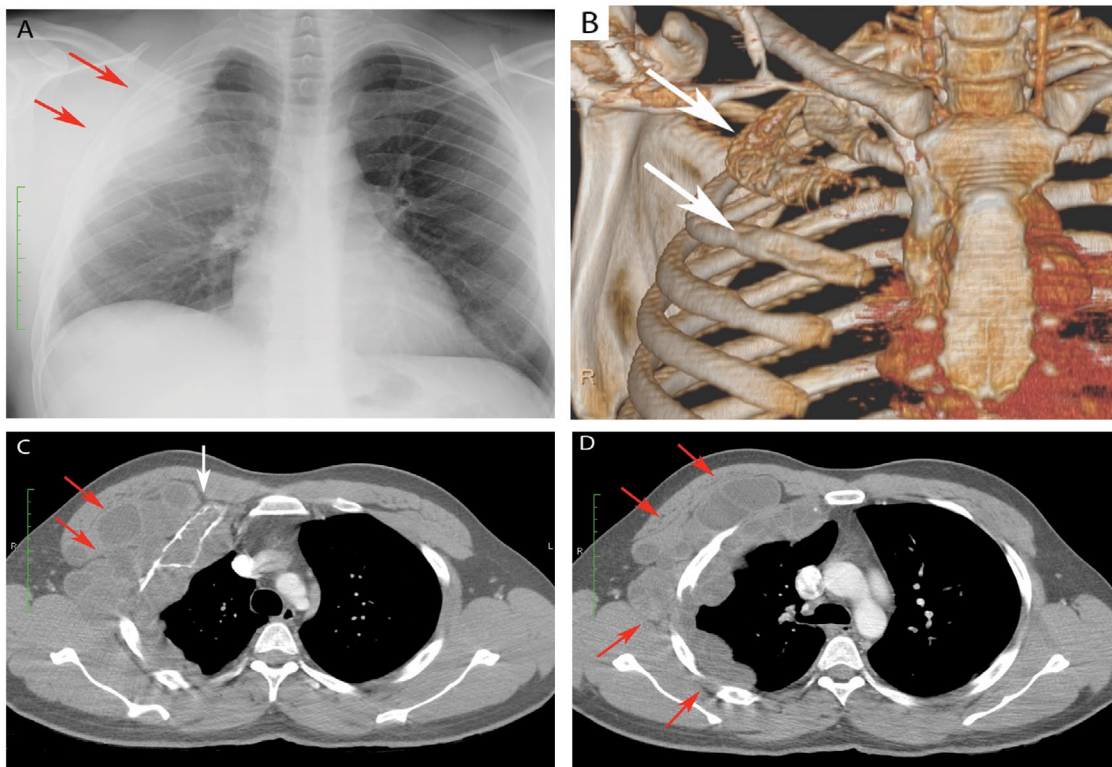
## Clinical case blog

### Title: Extensive Extra-Pulmonary Chest Wall Hydatidosis

Jacques Scherman<sup>1</sup>, Paul Scholtz<sup>2</sup>, Peter Zilla<sup>1</sup>, and Anthony Linegar<sup>1</sup>

<sup>1</sup>Chris Barnard Division of Cardiothoracic Surgery, Groote Schuur Hospital, University of Cape Town, South Africa

<sup>2</sup>Department of Radiology, Groote Schuur Hospital, University of Cape Town, South Africa



A 25-year old male patient, who grew up in a rural area endemic for hydatid disease, presented with a 1-year history of an increasingly painful and progressive enlarging swelling over his right anterior chest wall. A chest radiograph (A) and computed tomography (B-D) demonstrated extensive polycystic chest wall and pleural based opacities (red arrows) with cortical destruction and intramedullary lytic lesions involving the second and third ribs on the right (white arrows). Hydatid serology tested positive. The patient underwent uneventful surgical excision of more than thirty cysts, together with partial *en bloc* removal of the second and third ribs, followed by chest wall reconstruction. Adjuvant chemotherapy with Albendazole (400mg bi-daily) was continued for 3 months following surgery. The patient made a satisfactory recovery at three months follow up.