

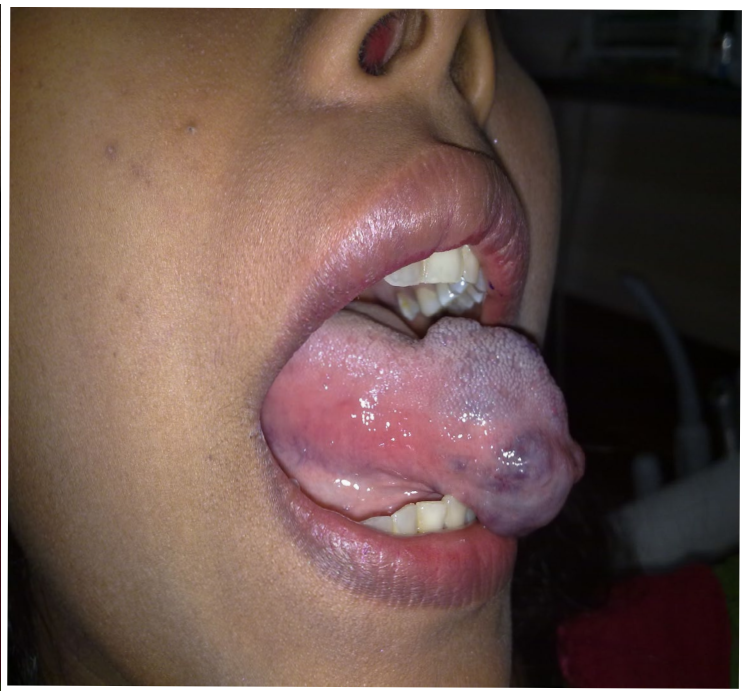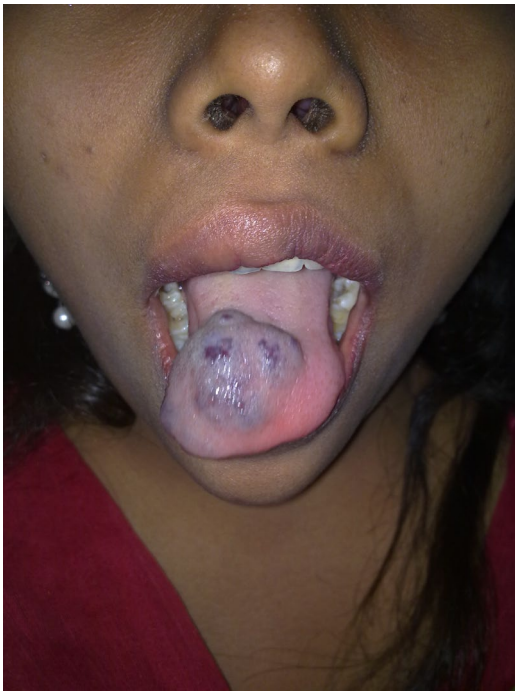
## Clinical case blog

### Title : Hemangioma of Tongue

Treville Pereira<sup>1</sup> and D. Y. Patil<sup>2</sup>

<sup>1</sup>Department of Oral & Maxillofacial Pathology and Microbiology

<sup>2</sup>Dental College & Hospital



Hemangiomas are benign proliferations of vessels that closely resemble normal vessels. Their similarity to normal vessels is so great that it is not clear that they represent vessel malformations true neoplasms or hamartomatous overgrowths. Some suggest that these lesions have a great number of endothelial cells than what are required to line their lumen while others suggest that they represent hamartomas.

Another school of thought says that the malformations that are present at birth or those that appear shortly after birth are congenital vascular malformations. Of these the Arteriovenous Hemangiomas are the most dangerous and is life threatening.

A 20 year old female patient reported to our dental clinic for routine dental treatment. On examination, we noticed a bluish swelling on the tongue of patient. She gave a history of the swelling present from the age of eleven years and a gradual increase in size over the last five years. She was also able to detect a “whirring sound” within the lesion. She also gave a history of frequently biting her tongue during mastication. However, the bleeding would stop after some time. Unfortunately the patient did not want to follow- up and hence further investigations could not be done.

Unlike the cavernous or capillary hemangiomas, this type is not present in infancy but emerges later during the teenage years. Although arteriovenous communications are apparent in these soft tissues, they do not pose significant bleeding risk because the vessels remain very small. Although some patients elicit a palpable thrill, they do not present uncontrollable bleeding associated with those in bone.