

Clinical Image

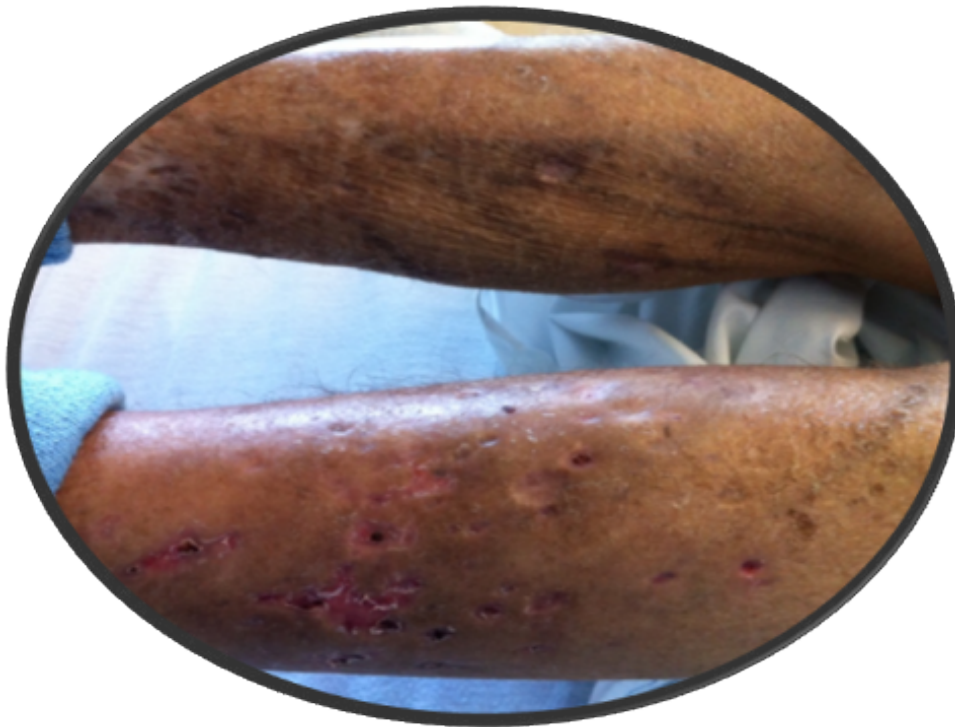
Title: Heroin Injection Marks Should Never be Missed on Physical Exam

Tariq Khurram¹, Farhangi Arezo² and Rana Fauzia³

¹Internal Medicine, University of Florida, USA

²Farhangi, Arezo, MD, Internal Medicine, Semnan University of Medical Sciences, Iran

³Rana, Fauzia, MD, Internal Medicine, University of Florida, USA



Acute heroin overdose is very common problem among urban and suburban populations in the United States. Heroin abusers inject the drug intravenously to attain the desired “rush” of euphoria which not only predisposes them to dependence but also makes these individuals vulnerable to HIV, Hepatitis, abscesses.