

Medical Image

Title: Intra-abdominal Testicular Seminoma

Alawad AAM and Faisal H. Younis FH*

Department of Surgery, Faculty of Medicine, University of Medical Sciences and Technology, Sudan

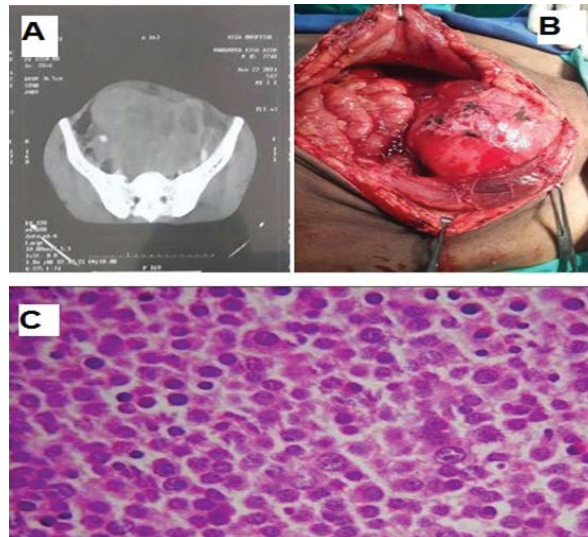


Figure 1: (A) Showed huge solid mass arising from the pelvis. (B) Abdominal mass during exploration. (C) Photomicrograph of intra-abdominal left testicular tumor-spermatocytic seminoma.

A 49-year-old man married with five children, with no known previous complaint presented to the surgical unit at University Charity Teaching Hospital with complaints of abdominal swelling for 4 months. He had been suffering from anorexia, weight loss during last two months. The patient experienced dragging pain in the hypogastrum during the last two months. On general examination the patient was found to be ill looking and mildly anemic. On local examination an intraabdominal mass was palpable. The abdominal mass was elongated occupying the whole right iliac fossa and extending into the hypogastrum (12 cm x 8cm approximately). The margins were ill defined, surface was irregular and consistency was hard. The lump was fixed with underlying structures and not tender. On examination of the inguinoscrotal region the left testis was found to be in place but the right testis was absent from the left scrotal sac.

Our provisional diagnosis was malignant tumor of the right intraabdominal testis. Investigations showed elevated alkaline phosphatase and B-HCG. Sperm analysis and alpha feto protein were within normal ranges. The CT scan showed a huge solid mass arising from the pelvis with calcification, no liver lesions or para-aortic lymph node enlargement (Figure 1A).

We went for laparotomy with lower midline incision and found a huge growth occupying the hypogastrum and the right iliac fossa (Figure 1B). The mass was inoperable. The histopathological examination revealed spermatocytic seminoma (Figure 1C).

The location of the undescended testis is identified with the probability of carcinogenesis with the intra-abdominal position having the highest risk for malignancy. Painless enlargement of the testis is the common presentation of malignancy in an undescended testis. Rarely, an abdominal testicular tumor can cause abdominal pain, abdominal mass, and haematuria because of adjacent visceral infiltration [1]. Seminomas tumors are extremely sensitive to chemotherapy and radiotherapy [2].

References

- Chatterjee S, Rynthathiag I, Ray U (2013) Chaudhury TK. Seminoma Arising from Intra-abdominal Cryptorchidism with Ipsilateral Renal Agenesis: A Rare Association. *Indian J Surg*. 75: 296-8.
- Yilmaz A, Bayraktar B, Sagirolgu J, Gucluer B (2011) Giant seminoma in an undescended testis presenting as an abdominal wall mass. *J Surg Case Rep* 12: 9.