

Clinical Image

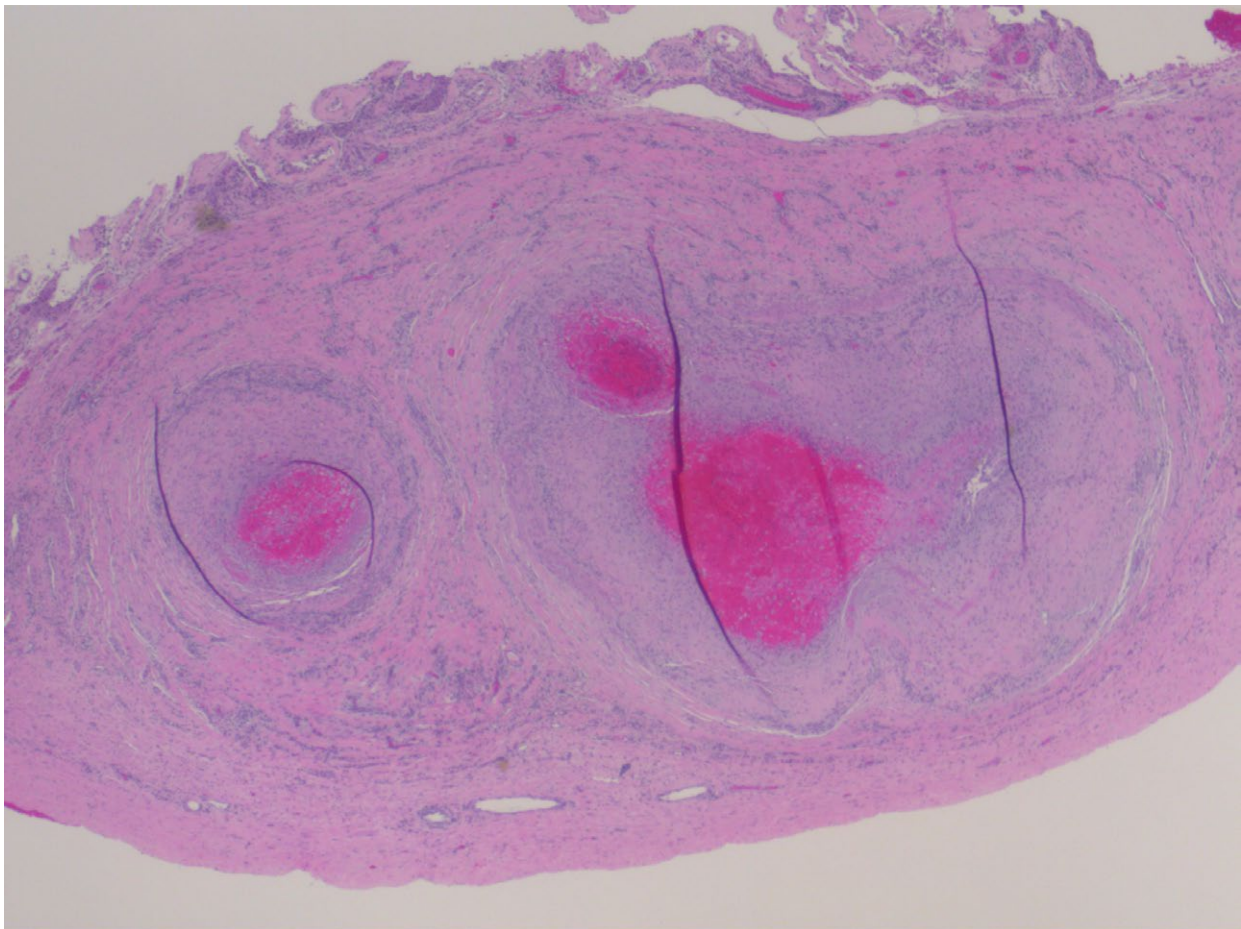
Title: Isolated Right Testicular PAN (Polyarthritis Nodosa) Presenting As Right Testicular Pain

Khurram T¹, Arezo F² and Fauzia R³

¹Tariq, Khurram, MD, Internal Medicine, University of Florida, USA

²Farhangi, Arezo, MD, Internal Medicine, Semnan University of Medical Sciences, Iran.

³Rana, Fauzia, MD, Internal Medicine, University of Florida, USA



Patient is a 30 year old male with no significant past medical history who repeatedly sought medical attention for debilitating right testicular pain. Initially he was symptomatically treated with non-steroidal anti-inflammatory medications for presumptive diagnosis of testicular trauma. A few months later he went to different emergency department and was treated with antibiotics for presumptive diagnosis of epididymitis. Finally at his third presentation he was hospitalized. Three testicular biopsies were taken and only the biopsy sample from the middle area of the right testes revealed polyarthritis nodosa. The Patient had no other signs and symptoms and this was likely isolated PAN of his right testes which is a very rare occurrence.