

Clinical-Medical Image

## Liver MRI with Contrast: A Comprehensive Guide to the Procedure and What to Expect

Roberto Moretto\*

Department of Surgery, Azienda Ospedaliero-Universitaria Pisana, Via Paradisa 2, 56124 Pisa, Italy

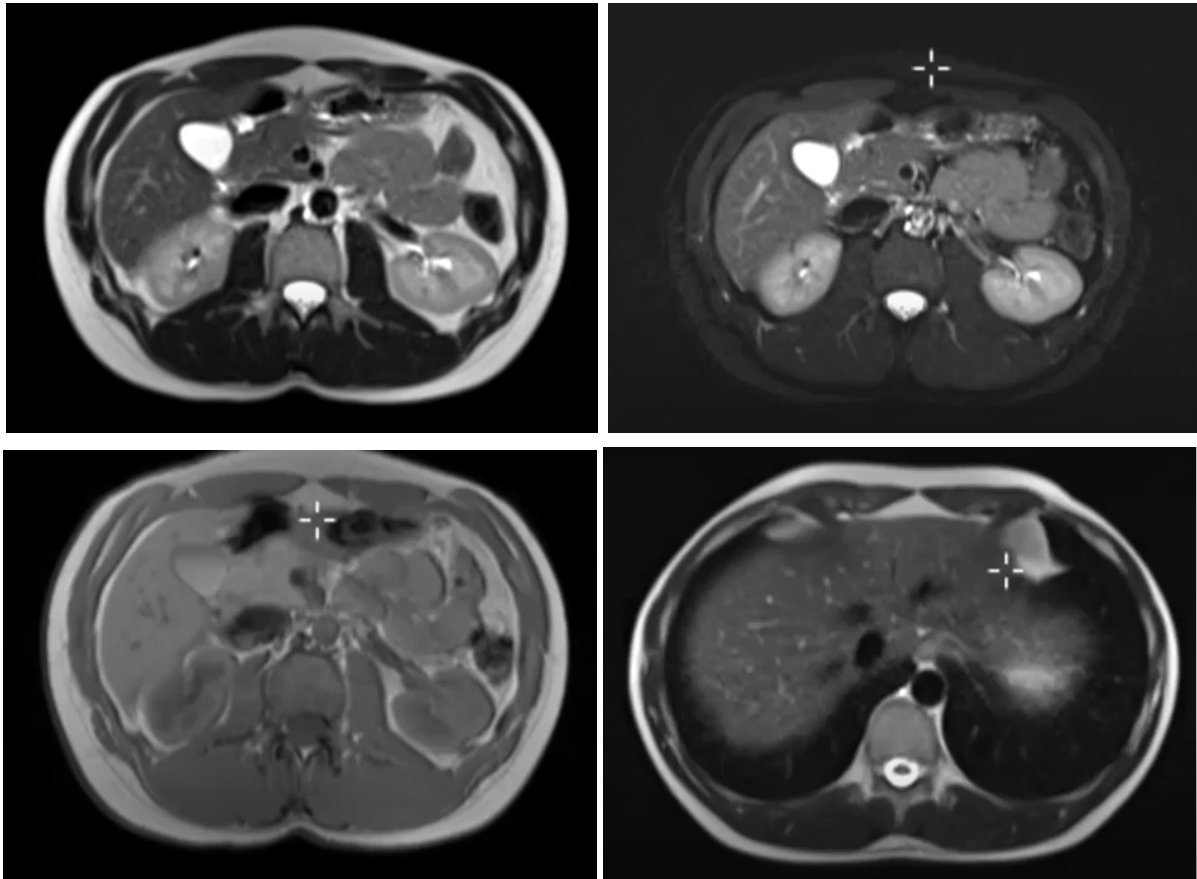


Figure 1: Liver MRI with contrast.

### Clinical-Medical Image

Liver MRI with contrast is a medical imaging procedure that uses magnetic resonance imaging (MRI) to produce detailed images of the liver. Contrast agents (also known as contrast dyes) are used to help highlight the liver and blood vessels, making it easier for doctors to see any abnormalities. The procedure usually begins with the patient lying on a table that is moved into the MRI machine. The technician will insert an intravenous (IV) line into the patient's arm or hand to administer the contrast agent. The patient will need to lie still during the procedure, which usually takes 30-60 minutes. During the MRI scan, the patient will hear loud banging or knocking sounds as the machine takes images. The technician may provide earplugs or headphones to help block out the noise. After the scan is complete, the IV line will be removed and the patient can resume normal activities. The images will be reviewed by a radiologist, who will provide a report to the patient's doctor. It is important to tell the doctor and technician if the patient has any allergies, kidney problems, or is pregnant, as these factors may affect the use of contrast agents in the MRI scan [1,2].

**Received:** 20 January 2023, Manuscript No. ijcmi-23-96523; **Editor assigned:** 21 January 2023, Pre QC No. P-96523; **Reviewed:** 13 February 2023, QC No. Q-96523; **Revised:** 18 February 2023, Manuscript No. R-96523; **Published:** 27 February 2023, DOI:10.4172/2376-0249.1000878

\***Corresponding author:** Roberto Moretto, Department of Surgery, Azienda Ospedaliero-Universitaria Pisana, Via Paradisa 2, 56124 Pisa, Italy; E-mail: roberto.mort@ao-pisa.toscana.it

**Citation:** Moretto R. (2023) Liver MRI with Contrast: A Comprehensive Guide to the Procedure and What to Expect. *Int J Clin Med Imaging* 10:878.

**Copyright:** © 2023 Moretto R. This is an open-access article distributed under the terms of the Creative Commons Attribution License, which permits unrestricted use, distribution and reproduction in any medium, provided the original author and source are credited.

**Keywords:** *Echinococcosis*; Liver; Cysts; Pair; Surgery

### **Conflict of Interest**

None of the authors has any conflicts of interests to disclose.

### **References**

- [1] Gupta A, Caravan P, Price WS, Platas-Iglesias C and Gale EM. (2020). Applications for transition-metal chemistry in contrast-enhanced magnetic resonance imaging. *Inorg Chem* 59: 6648-6678.
- [2] Wahsner J, Gale EM, Rodríguez-Rodríguez A and Caravan P. (2018). Chemistry of MRI contrast agents: current challenges and new frontiers. *Chem Rev* 119: 957-1057.