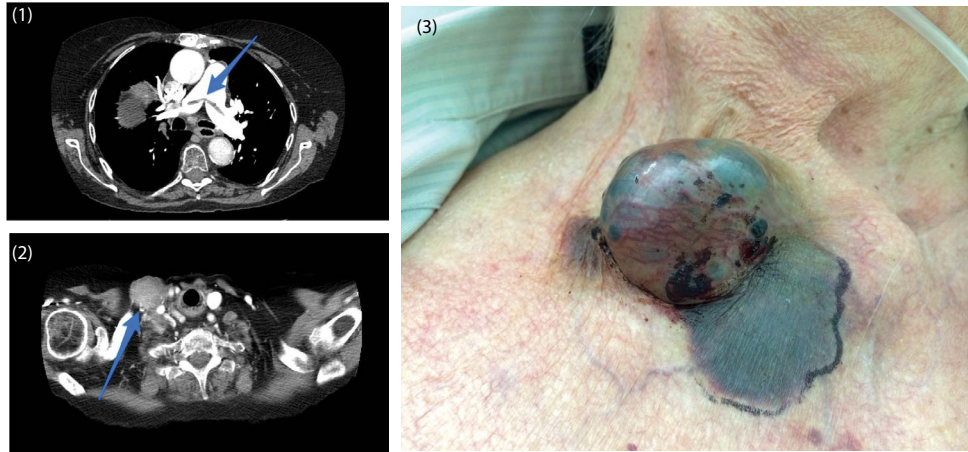


Case Blog

Title: Lymph-node Metastasis in Advanced Papillary Thyroid Cancer

Tarantini F* and Modina D

Hospital Pope John XXIII, Piazza WHO - World Health Organization, 1-24127 (BG), Italy



An 86-years-old woman was admitted with massive pulmonary embolism. TC-scan revealed a saddle embolus bridging the main pulmonary artery bifurcation (Figure 1). A solid mass 3.5cm diameter at the base of the right side of the neck was also present (Figure 2). Physical examination showed a swollen formation 3-4cm, compact, purple- bluish in the same location (Figure 3). A past history of thymoma treated with surgery and beam-radiation, was followed by a diagnosis of papillary thyroid carcinoma (PTC) five years ago. She underwent thyroidectomy + lymphadenectomy. After one year, right laterocervical lymphadenectomy + treatment with I-131 because of massive metastasis of PTC. One year ago, again right laterocervical lymphadenectomy, as PET-scan detected metastasis-Histology confirmed PTC. The present new lesion appeared a few months before, it was not treated according to patient's will, and grew. Doppler-US of lower limbs was negative for DVT. She was treated with low-molecular-weight heparin. Patients aged >45 years affected by PTC with lymph-node metastasis recurrence have worst prognosis.