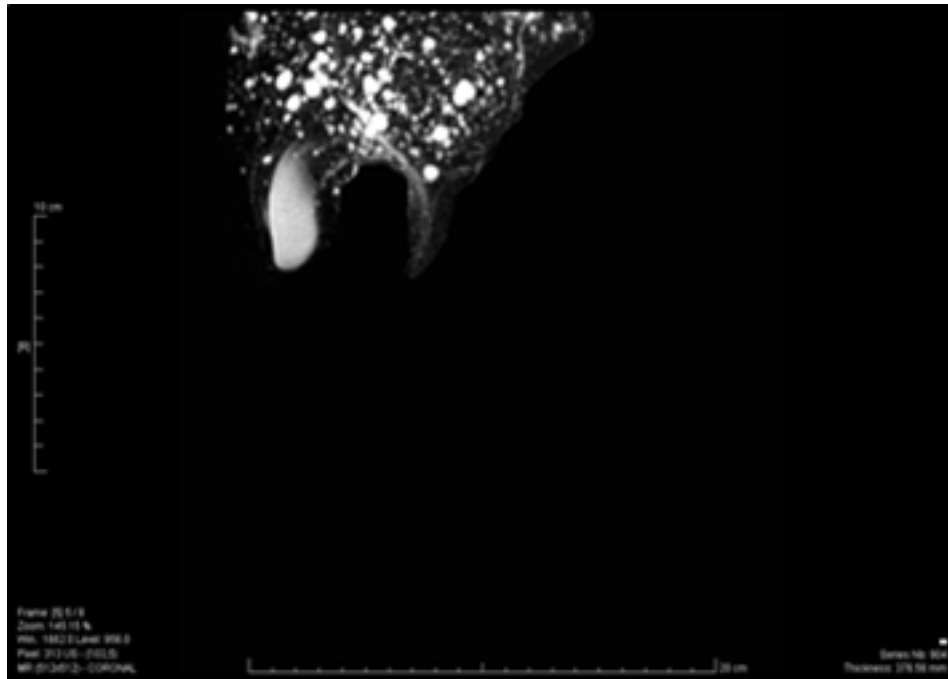


## Clinical Image

### Title: Magnetic Resonance Cholangio Pancreatography

Monica Henriques



Magnetic Resonance Cholangio Pancreatography (MRCP) with multiple small cystic formations, with intimate anatomical relation with biliary branches, randomly distributed in hepatic parenchyma