

Clinical-Medical Image

Mammary Metastasis of Renal Leiomyosarcoma

Onana Remy^{1*}, Akimana G¹, Melang A², Sanama C³ and Errihani H¹

¹Department of Medical Oncology, National Institute of Oncology, Rabat, Morocco

²Department of Urology, Mohammed V Military Teaching Hospital, Rabat, Morocco

³Department of Nephrology, Mohammed V Military Teaching Hospital, Rabat, Morocco

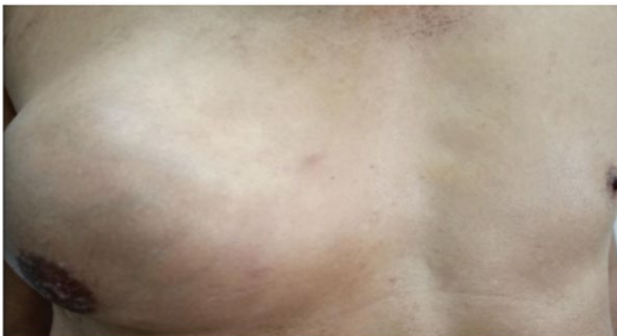

Figure 1: Image showing the right breast swelling of the patient.

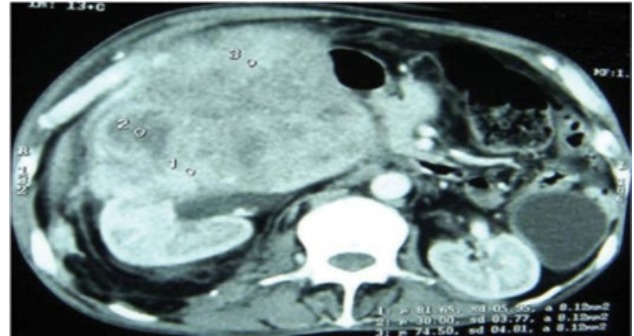


Figure 2: Tom densitometry of the abdomen showing a heterogeneous right renal mass.

Clinical-Medical Image

We report the case of a male patient, 58 years old, with no specific medical history. He consulted in October 2018 for gross hematuria and chronic lower back pain and abdominal pain since 2 months. Within this period, he has lost weight of about 4 kg, and has noticed swelling at the right lumbar region which has been increasing gradually. A Computer Tomography (CT) Scan showed a right renal tumor process evoking firstly a sarcoma (Figure 1). Then, he underwent a radical nephrectomy and histology confirmed the diagnosis of renal leiomyosarcoma with positive immunostaining for actin, desmin and negative with Pan-CK and S-100. After 3 years of good control, The patient presented a right breast swelling whose biopsy revealed a breast localisation of a leiomyosarcoma compatible with the known renal origine (Figure 2). The established diagnosis was a mammary metastasis of renal leiomyosarcoma and the patient received Doxorubicine protocol in a palliative strategy with stable response.

Keywords: Breast; Leiomyosarcoma; Metastasis

Declaration of Conflicting Interests

The authors declared no potential conflicts of interest with respect to the research, authorship, and/or publication of this article.

References

- [1] Tokpo AJ, Mohammadine B, Stitou K, Lakhdar F, Benzagmout M, et al. (2021) Unruptured Delivery of Posterior Fossa Hydatid Cyst in Child. *Int J Clin Med Imaging* 8:756.

Received: 01-Feb-2022, Manuscript No. IJCM-22-53007; **Editor Assigned:** 02-Feb-2022, PreQC No. IJCM-22-53007(PQ); **Reviewed:** 17-Feb-2022, QC No. IJCM-22-53007; **Revised:** 22-Feb-2022, Manuscript No. IJCM-22-53007 (R); **Published:** 28-Feb-2022, DOI:10.4172/2376-0249.1000813

***Corresponding author:** Onana Remy, Department of Medical Oncology, National Institute of Oncology, Rabat, Morocco, Tel: +21269052480; E-mail: onanaremy@yahoo.fr

Citation: Remy O, Akimana G, Melaung A, Sanama C and Errihani H (2022) Mammary Metastasis of Renal Leiomyosarcoma. *Int J Clin Med Imaging* 9:813.

Copyright: © 2022 Remy O, et al. This is an open-access article distributed under the terms of the Creative Commons Attribution License, which permits unrestricted use, distribution, and reproduction in any medium, provided the original author and source are credited.