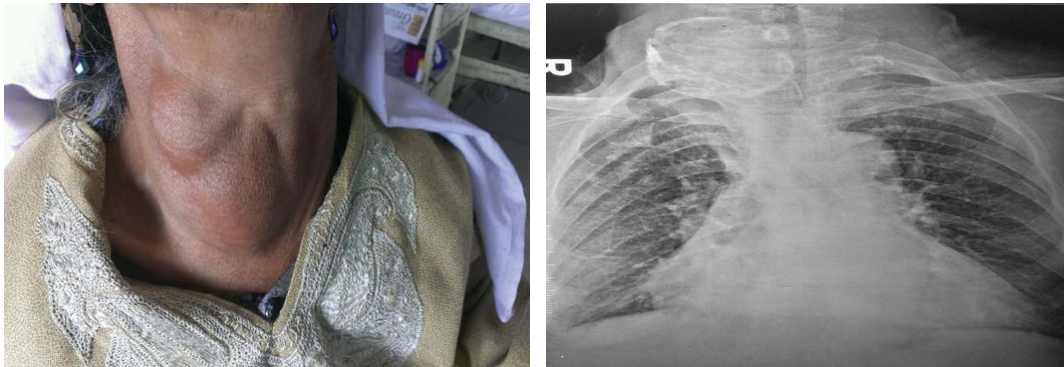


Medical Image

Title: “Ostrich Eggshell” Calcification in Toxic Multinodular Goitre

Dar WR*

Department of Medical Oncology, Sheri Kashmir Institute of Medical Sciences, Soura, Srinagar, Jammu and Kashmir, India



A 75 year old female was admitted with dysphagia and dyspnea that was gradual in onset and progressive in nature. Patient had a history of toxic multinodular goiter and was currently on carbimazole. Examination revealed a hugely enlarged thyroid gland that was firm to hard in consistency. X-ray neck revealed revealed a calcified thyroid gland that looked like an Ostrich Eggshell. Thyroid profile was suggestive of drug induced hypothyroidism. Patient is planned for thyroidectomy to relieve her of obstructive symptoms after her thyroid functions return to normal. In addition she will receive thyroxine supplementation that will continue lifelong. Eggshell calcifications are common in goiter but the one reported by us has not been previously reported.