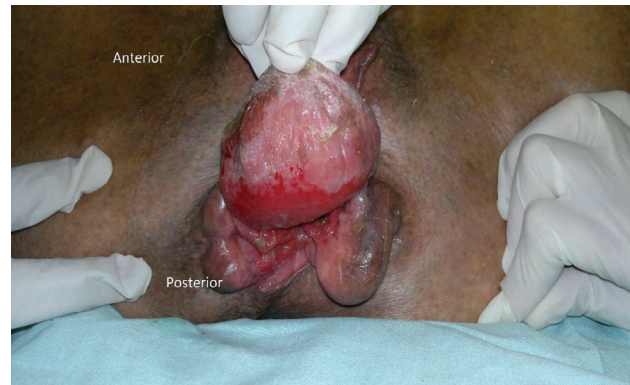


Clinical-Medical Image

## Peri-Anal Von Recklinghausen Syndrome

Henrique Fillmann\* and Lucio Sarubbi Fillmann

Catholic University, PUC-RS, Porto Alegre, Brazil



**Figure 1:** Large neurofibroma of the anal verge.

### Clinical Image

A 50-year-old woman arrived at the emergency unit of our hospital with anal pain and prolapse. She had 3 subcutaneous tumors at the anal margin and several similar tumors on her whole body. These tumors started to appear with the age of 15 and those at the anal margin grew more recently. She had no significant medical history and had 3 routine gynecological evaluations during the past 20 years. The physical examination suggests the possibility of a Von Recklinghausen Syndrome. We performed a surgical excision of the anal tumor and the histological analyses confirmed a neurofibromatosis type 1 (NF1). Neurofibroma is a disease of the peripheral nervous system and has been reported to involve the skin, subcutaneous tissue and viscera of almost all areas of the body. A neurofibroma involving the anal canal is a rare entity, with only few reports in the literature. Although rare, these tumors should be considered in the differential diagnosis of patients presenting with an anal mass (Figure 1).

**Keywords:** Neurofibroma; Von Recklinghausen, Anal

\*Corresponding author: Henrique Fillmann, Catholic University, PUC-RS, Porto Alegre, Brazil, E-mail: henrique@fillmann.com.br

Citation: Fillmann H, Fillmann LS (2020) Peri-Anal Von Recklinghausen Syndrome. *Int J Clin Med Imaging* 7: 713.

Copyright: © 2020 Fillmann H, et al. This is an open-access article distributed under the terms of the Creative Commons Attribution License, which permits unrestricted use, distribution, and reproduction in any medium, provided the original author and source are credited.