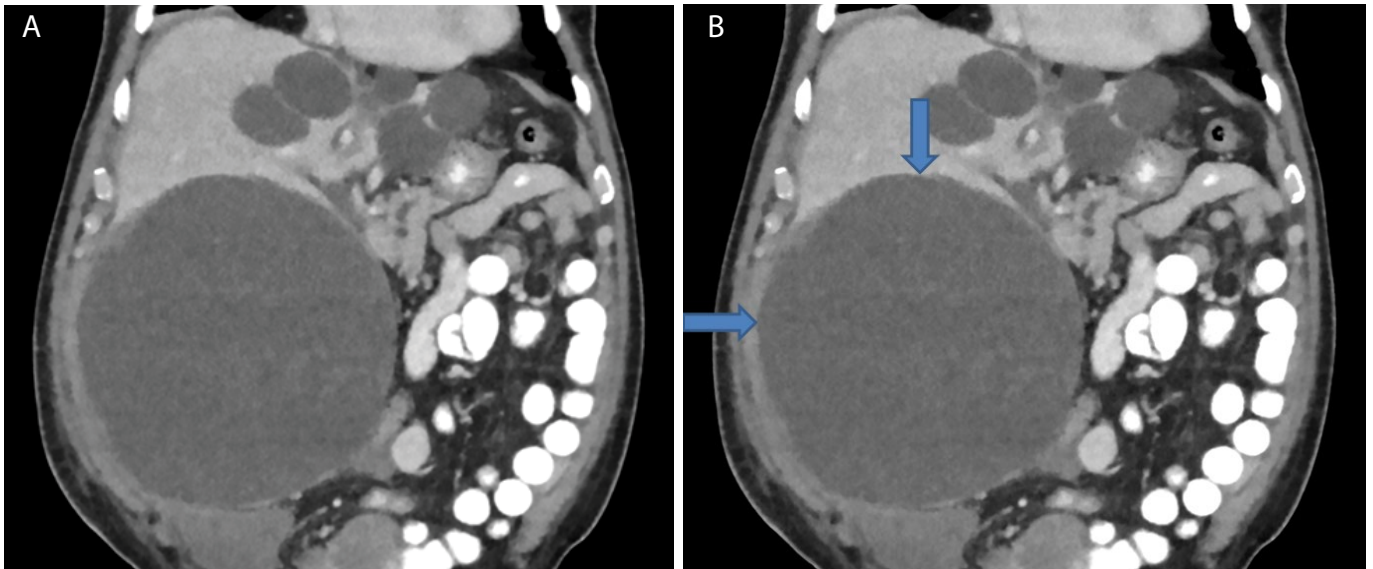


## Clinical Medical Image

### Title: Polycystic Liver Disease

Linda Nguyen\*

5501 Old York Road, Philadelphia, PA 19141, USA



Panel A: CT abdomen and pelvis.

Panel B: CT abdomen and pelvis with arrows.

A 77-year-old African American male presented with intermittent abdominal pain for one week. He denied nausea, vomiting, diarrhea, constipation, fevers, anorexia, or weight loss. He denied a family history of liver disease, recent travel, or history of intravenous drug abuse. His vital signs were normal. Labs revealed total bilirubin of 1.5 mg/dl, hypoalbuminaemia 3.0 gm/dl and prolonged prothrombin time of 14.8 sec. Computed Tomography of the abdomen and pelvis with contrast showed multiple hepatic cysts with the largest cyst occupying the right abdomen, measuring 20.6 cm (Panel A and Pelvis B). This cyst had predominantly fluid attenuation, but also contained several septations. The patient underwent laparoscopic fenestration of the large hepatic cyst with hepatic cyst wall biopsy. Pathology revealed blood without malignant cells. The patient tolerated the procedure well with improvement of his abdominal pain and normalization of his liver function tests and coagulation profile.