

Clinical Image

Title: Primary Lymphedema

Omar Farooq, Mohd. Iqbal* and Samia Rashid

Department of medicine, SMHS Hospital , Srinagar Kashmir, India

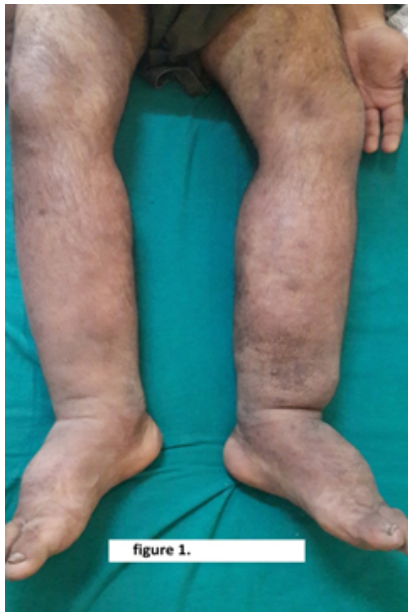

figure 1.

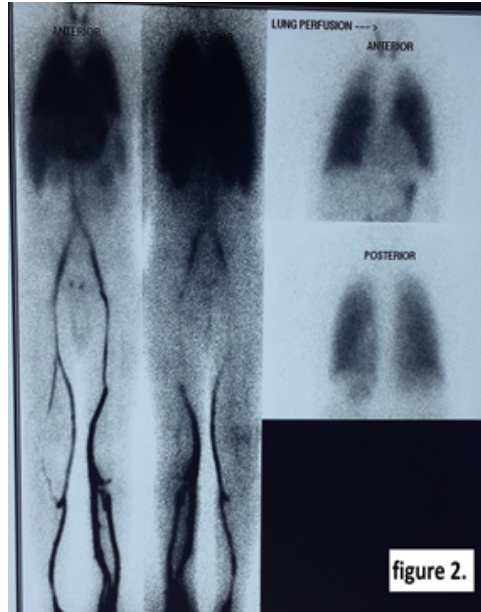


figure 2.

24 years old male presented with complaints of progressive oedema involving lower limbs. Oedema had started in right lower limb soon after birth and has been slowly increasing over the years involving the left lower limb as seen in Figure 1. Patient was evaluated, dual phase ascending venography with lung scan showed a normal venous system and lung scan (Figure 2). All the secondary causes were ruled out. Lymphoscintigraphy of both lower limbs shows delayed visualisation of popliteal and inguinal lymphnodes right greater than left confirming lymphatic dysfunction due to partially developed lymphatics.