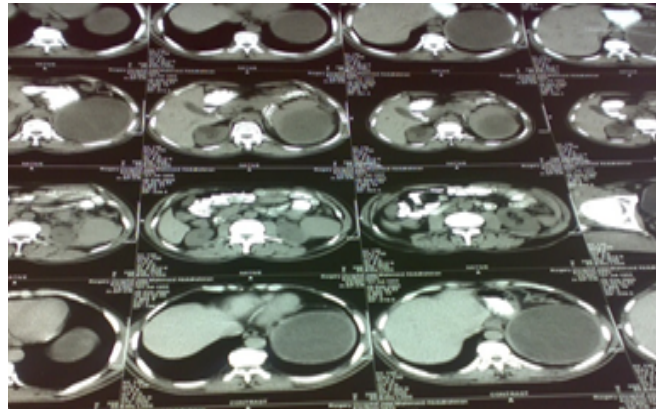
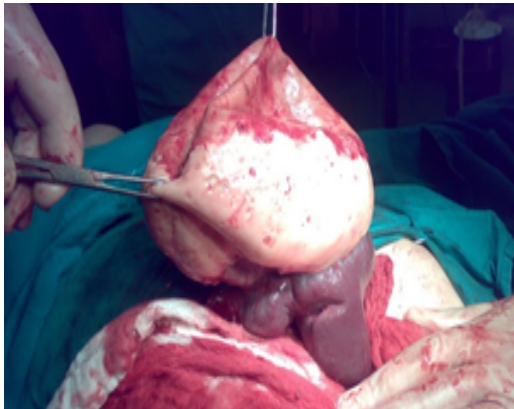

Clinical case blog

Title: Primary Splenic Cyst

Ali MH Al-Khayat* and Uday YH Abdullah

Faculty of Medicine and Health Sciences, University Sultan Zainal Abidin, Malaysia



A 63-year-old male patient complains of vague left-sided upper abdominal pain was admitted to hospital. Physical examination and the general well-being were otherwise normal. The CAT scan examination revealed a 17X16 cm. well-circumscribed cystic lesion in the upper pole of the spleen. Total surgical removal was successful with a complete uneventful recovery of the patient. Histological examination revealed primary splenic cyst. Among others, this type of cystic lesion of the spleen is rarely reported.