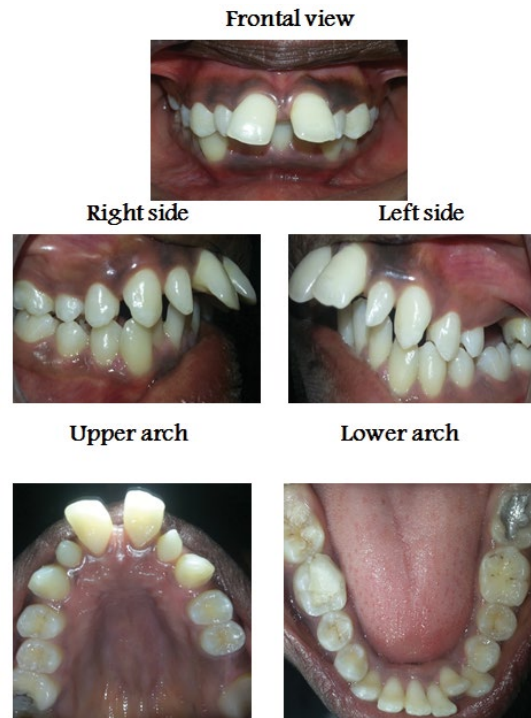


Medical Image

Title: Proclined Upper Central Incisors with Bilateral Peg Shaped Upper Lateral Incisors

Amal H. Abuaffan*

Department of Orthodontic, Pedodontics and Preventive Dentistry, University of Khartoum, Sudan



- Sudanese adult female had proclined upper permanent central incisors HOV= 11 mm and complete deep bite.
- Bilateral peg shaped upper permanent lateral incisors.
- Midline diastema=5 mm with disto labial inclined both upper central incisor.
- Missing upper left first permanent molar.