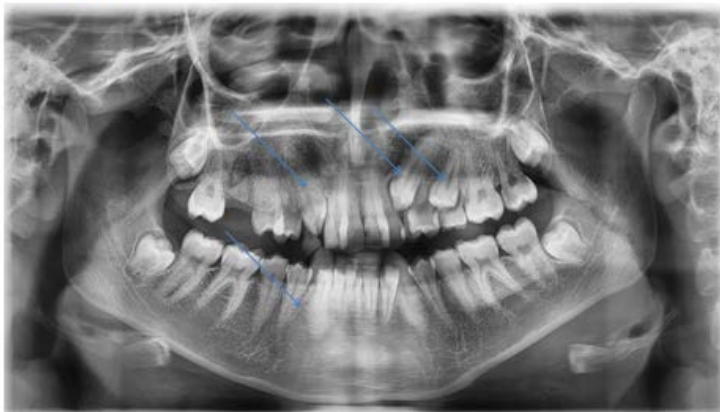


Title: Retained Deciduous and Impacted Permanent Teeth Together with Anterior and Posterior Carious Teeth

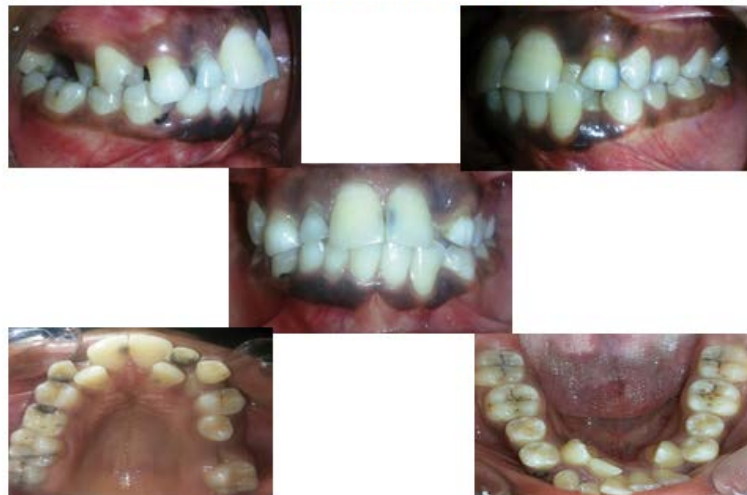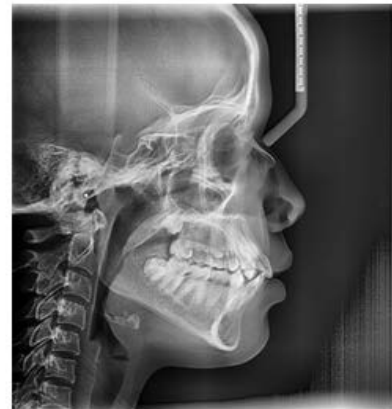Amal H. Abuaffan*

Department of Orthodontic, Pedodontics and Preventive Dentistry, University of Khartoum, Sudan

Orthopantomogram shows impacted upper Right canine & Left canine and first premolar



Cephalometric view: Normal skeletal relation



University Student 20 years old presented with the following problems:

UN erupted upper and lower permanent incisors and canines due to retained deciduous one.

Caries in the permanent central incisors and posterior molars.

Remaining root of deciduous canine lower right side.

*Corresponding author: Amal H. Abuaffan, Department of Orthodontic, Pedodontics and Preventive Dentistry, University of Khartoum, Sudan, Tel: 00249912696035; E-mail: amalabuaffan@yahoo.com

Copyright: © 2015 Abuaffan AH. This is an open-access article distributed under the terms of the Creative Commons Attribution License, which permits unrestricted use, distribution, and reproduction in any medium, provided the original author and source are credited.