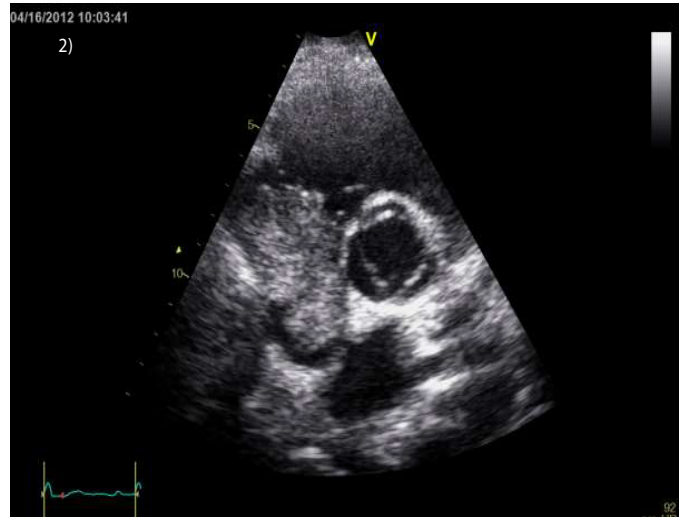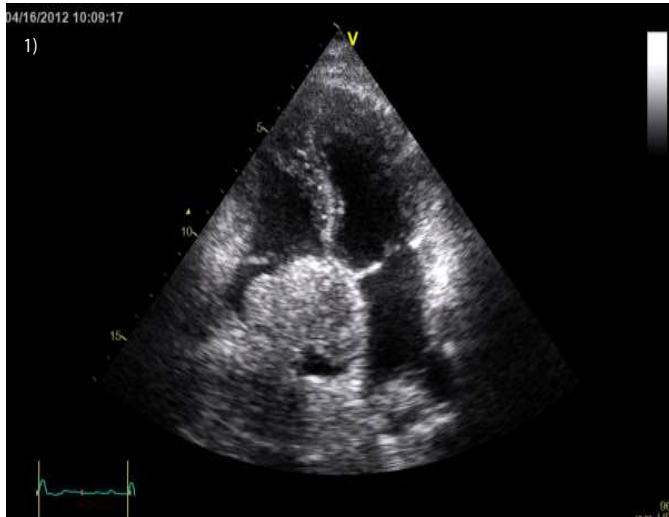


Clinical case blog

Title : Right Atrial Mass in a Patient with HIV & Hepatitis B

*Muhammad U Siddiqui

Internal Medicine resident, Department of Medicine, Mount Sinai Hospital-Englewood program, USA



A 41 year old man presented to the emergency room for evaluation of substernal chest pain, shortness of breath and generalized failure to thrive. Patient had history of hepatitis B and HIV being treated with Truvada and Kaletra. On Echocardiogram patient was noted to have a large mass filling the right atrial cavity. CT scan of abdomen, pelvis and chest showed a diffusely enlarged heterogeneously enhancing liver consistent with large hepatoma, with portal venous and hepatic vein thrombosis. Tumor thrombus extended through the hepatic veins and upper inferior vena cava into the right atrium. There was 6 cm greatest diameter enhancing mass in the right atrium.