

Case Blog

Title: Subcutaneous Emphysema

Amit Bhowmik^{1*} and Tina Roy Bhowmik²

¹Department of Emergency Medicine, Glocal Hospital, Krishnanagar, Nadia, West Bengal, India

²Glocal Hospital, Krishnanagar, Nadia, West Bengal, India

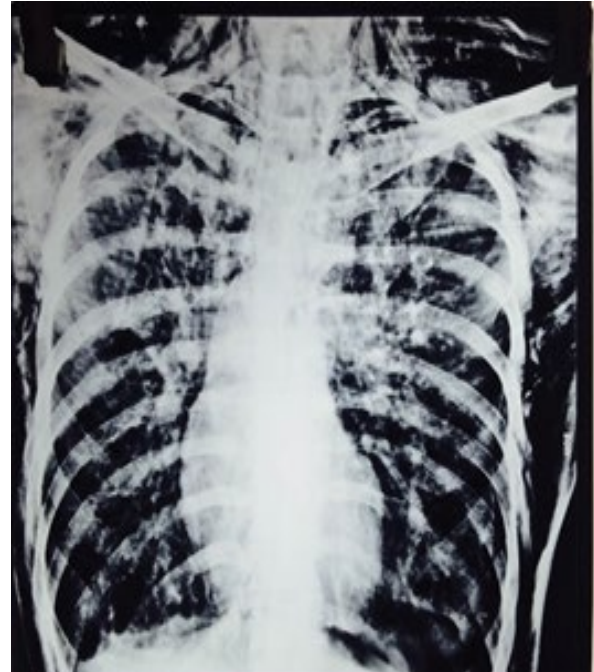
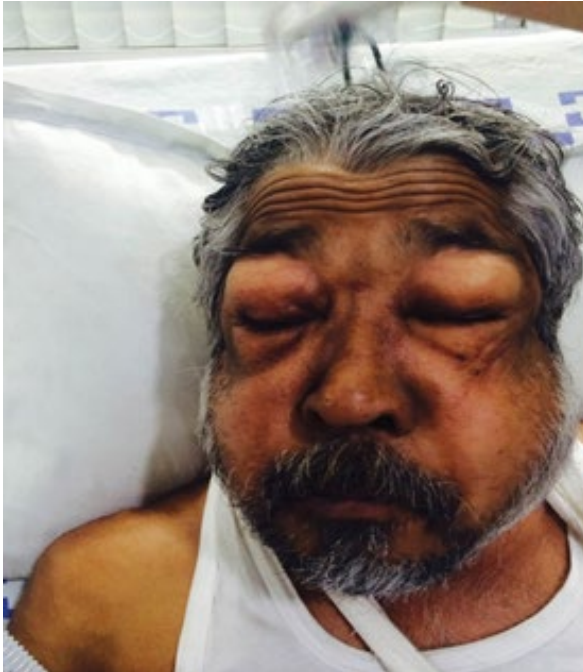

Figure 1: Extensive sub-cutaneous emphysema.

Figure 2: X-ray showing extensive emphysema of lungs with a small pneumothorax (left).

A 58-year-old male patient, a known case of Chronic Obstructive Pulmonary Disease (COPD), reported to the emergency of Glocal Hospital, Krishnanagore, India, in a state of severe breathlessness. On examination, it was revealed that in addition to COPD, he developed extensive sub-cutaneous emphysema spreading from below the scalp to the legs. A chest X-ray showed emphysematous lungs with air and a small pneumothorax. His condition improved with conservative treatment and emphysema is gradually disappeared. This is a unique and rare case of extensive sub-cutaneous emphysema spreading from scalp up to the legs in a setting of COPD (Figures 1 and 2).

Acknowledgement

The authors gratefully acknowledge for giving permission to publish the photograph and x-ray.