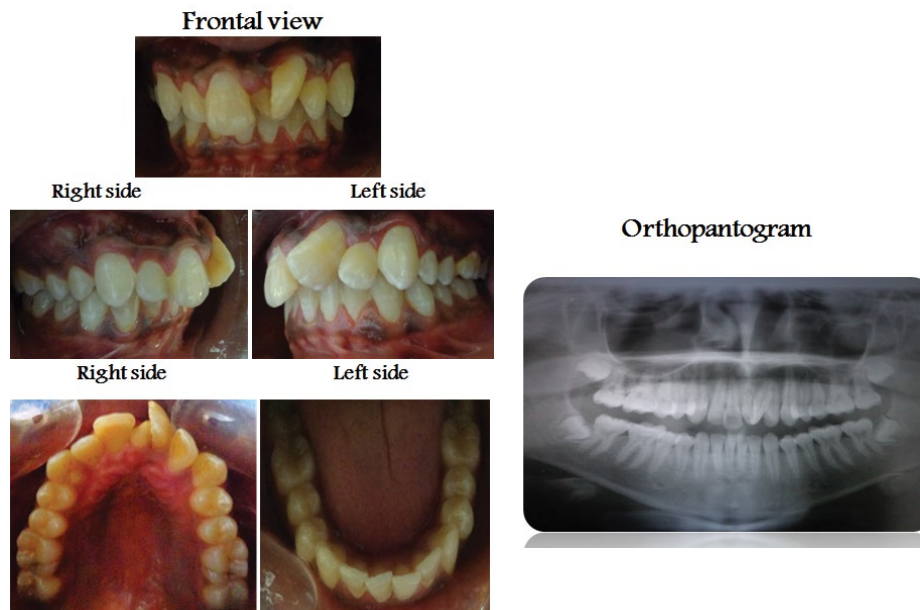


Medical Image

Title: Supernummary Tooth between Upper Central Incisors with 90 Degree Rotation Upper Left Incisors

Amal H. Abuaffan*

Department of Orthodontic, Pedodontics and Preventive Dentistry, University of Khartoum, Sudan



- Male 45 years old had Supernummary tooth (mesiodense) between the upper permanent central incisors resulted in mesio-labial rotation 90 degree of the upper left central incisors.