

Clinica-Medical Image

The Villous Black Tongue

Sara Daoudi*, Adrif I and Errihani H

Department of Medical Oncology, National Institute of Oncology, Rabat, Morocco

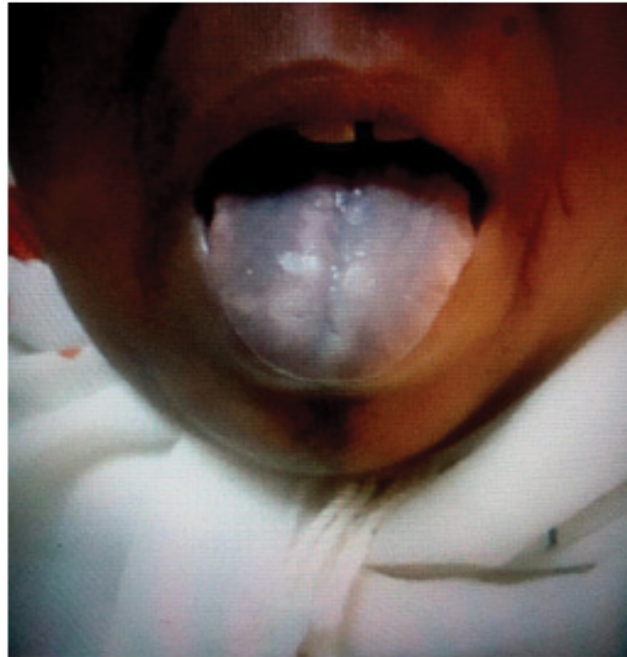


Figure 1: The villous black tongue after chemotherapy.

Clinical Image

We report the case of a 45-year-old female patient, non-smoking, who has a colon cancer for which she received chemotherapy by capecitabine. The patient presented three weeks after the first cure, a burning pain on the tongue with a bad taste sensation. The clinical examination found a blackish color on the tongue corresponding to the villous black tongue (Figure 1). A swab of the tongue and throat was taken and the bacteriological examination came back negative. The patient received a treatment based on mouthwashes by sodium bicarbonate, combined with twice-daily oral hygiene with scraping and brushing the back of the tongue. The evolution was favorable.

Keywords: Black tongue; Colon cancer; Chemotherapy

*Corresponding author: Sara Daoudi, Department of Medical Oncology, National Institute of Oncology, Rabat, Morocco; E-mail: saralys14@gmail.com

Citation: Daoudi S, Adrif I, Errihani H (2020) The Villous Black Tongue. *Int J Clin Med Imaging* 7: 689.

Copyright: © 2020 Daoudi S, et al. This is an open-access article distributed under the terms of the Creative Commons Attribution License, which permits unrestricted use, distribution, and reproduction in any medium, provided the original author and source are credited.
