

Medical Image

Title: Unusual Cause of Gastric Outlet Obstruction

Jagtap Nitin*, Shrimal Pankaj Kumar, Singh Jagadeesh R and D Nageshwar Reddy

Asian Institute of Gastroenterology, Hyderabad, India

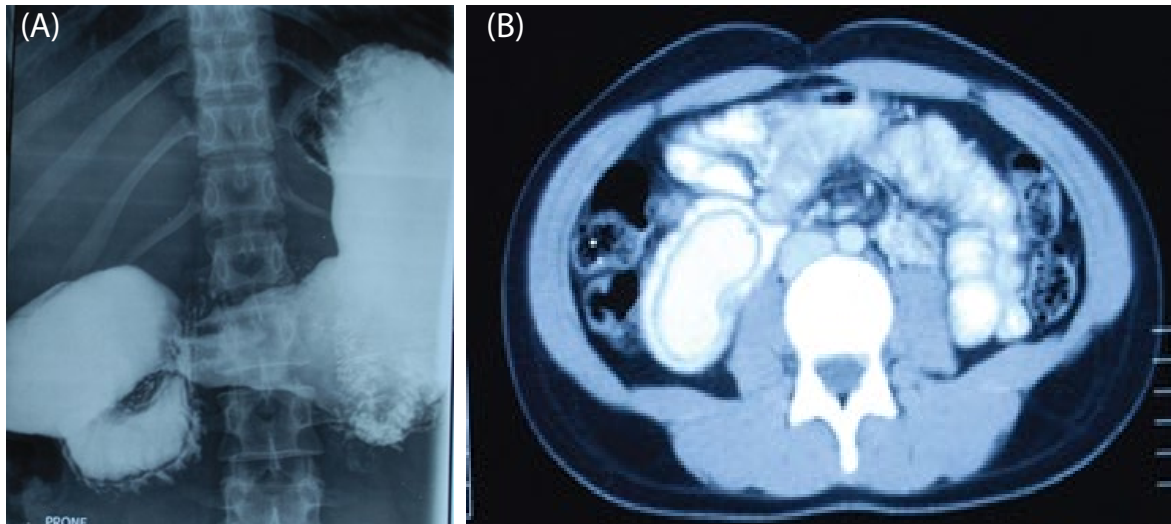


Figure A: Duodenum surrounded by radiolucent band.

Figure B: CECT abdomen revealed contrast material-filled diverticulum.

A 23 year old female was presented with post prandial epigastric fullness and vomiting since 4 months. Her barium meal showed sack-like filling lesion in duodenum surrounded by radiolucent band (Figure A). CECT abdomen revealed contrast material-filled diverticulum (Figure B). She underwent duodenotomy and diverticulum excision.