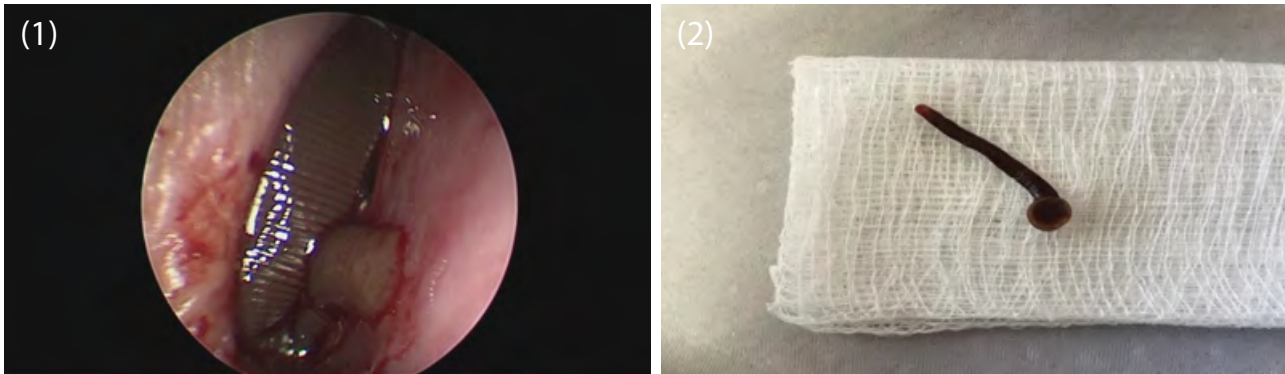


Case Blog

## Unusual Presentation of a Leech in the Nose

Meenakshi A\*, Philip R and Sreetharan SS

Department of Otorhinolaryngology, Hospital Raja Permaisuri Bainun, Ipoh, Malaysia



**Figure 1:** Nasal endoscopic view of leech in the right nostril.  
**Figure 2:** Leech removed from the nasal cavity.

A 56 year old lady with no comorbidity, presented with right sided epistaxis for 2 weeks. She recently went swimming in the river two weeks ago. Nasal endoscopy done in clinic, noted a leech in the right nostril (Figure 1) which was successfully removed under local anaesthesia in clinic (Figure 2). She was asymptomatic and well after that.

**\*Corresponding author:** Meenakshi A, Department of Otorhinolaryngology, Hospital Raja Permaisuri Bainun, Ipoh, Malaysia; Tel: 012-5138619; E-mail: [meeena81@hotmail.com](mailto:meeena81@hotmail.com)

**Citation:** Meenakshi A, Philip R, Sreetharan SS (2016) A Case of Chemical Pneumonia Due to Paint Thinner Exposure. *Int J Clin Med Imaging* 3: 473. doi:10.4172/2376-0249.1000472

**Copyright:** © 2016 Meenakshi A, et al. This is an open-access article distributed under the terms of the Creative Commons Attribution License, which permits unrestricted use, distribution, and reproduction in any medium, provided the original author and source are credited.