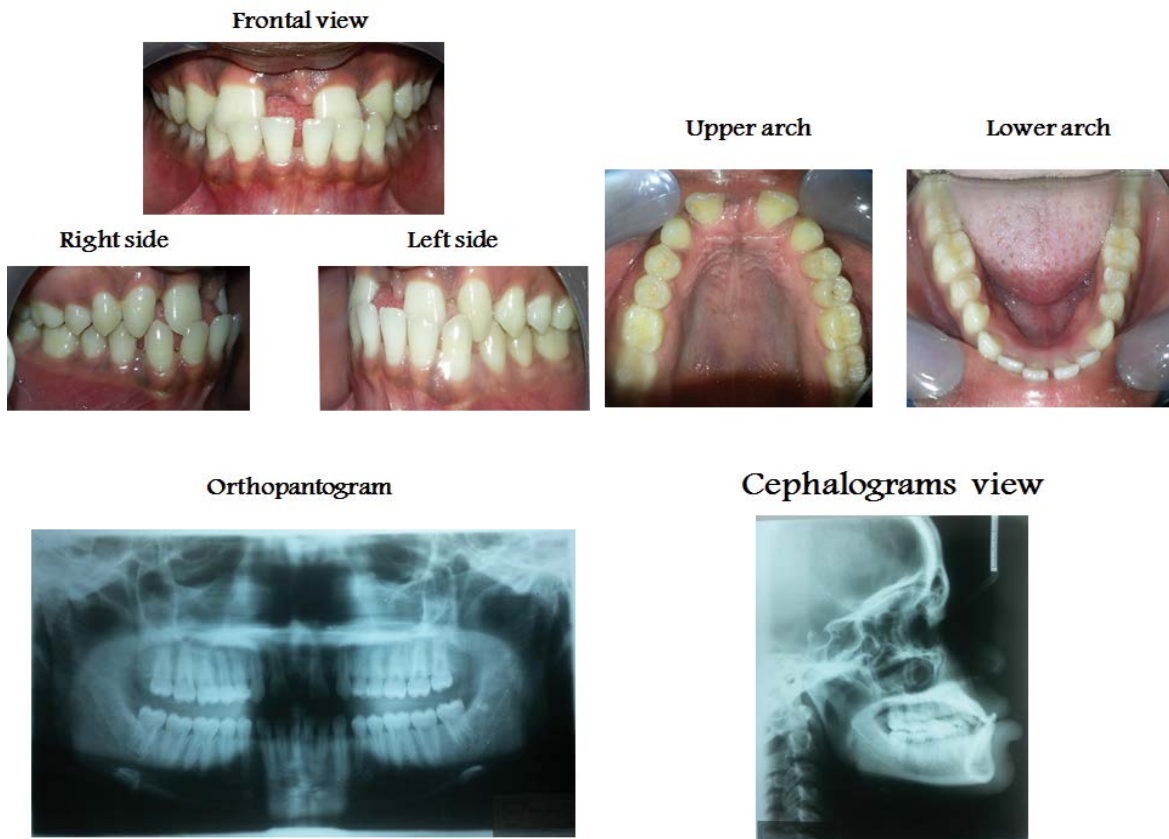


## Medical Image

### Title: Upper Mid Line Diastema with Bilateral Congenitally Missing Upper Lateral Incisors

Amal H. Abuaffan\*

Department of Orthodontic, Pedodontics and Preventive Dentistry, University of Khartoum, Sudan



Sudanese boy 25 year old had 15 mm midline diastema result from congenitally missing permanent upper lateral incisors bilaterally.

#### Dental:

CI: I molar and canine.

CI: III incisors and reverse over jet=-5 mm.

Skeletal Class III malocclusion.