

Medical Image

Uterine Apoplexy

Mohamed Achraf Grohs*

NB12 Rue Kurd ali Kenitra, Morocco

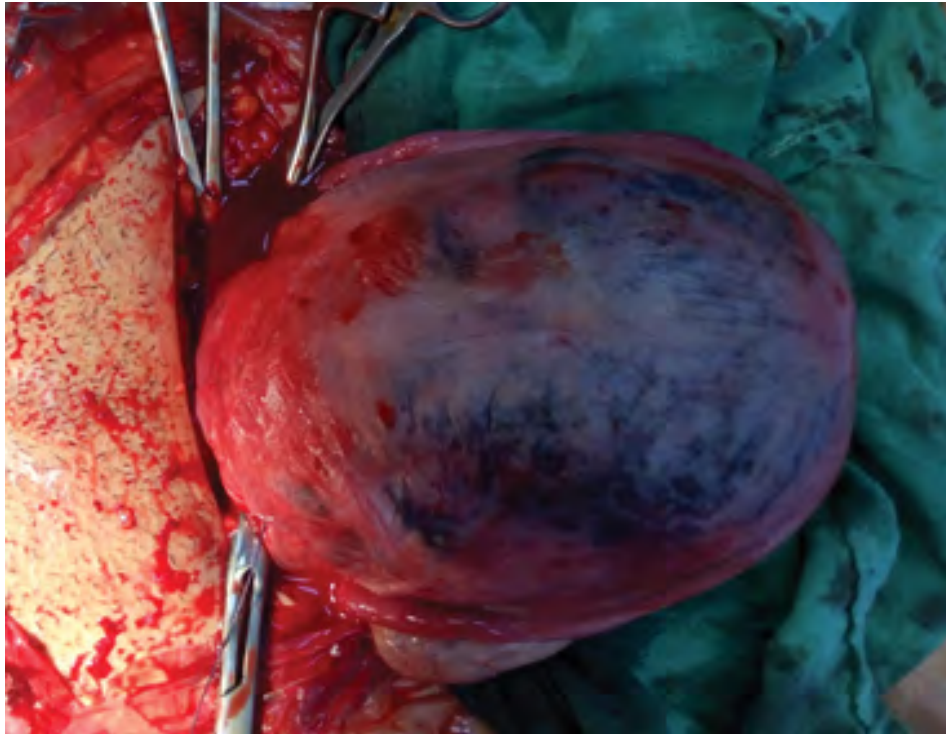


Figure 1: Uterine preeclampsia

Medical Image

A 19 years primigravida of 38 weeks pregnancy by date was admitted in the labor room with diagnosis of preterm labor with preeclampsia. Ultrasonography revealed 36 weeks pregnancy with normal placenta position. Lower segment caesarean section was done for severe fetal distress with preeclampsia (Figure 1).

*Corresponding author: Mohamed Achraf Grohs, NB12, Rue Kurd ali, Kenitra, Morocco; E-mail: achraf.grohs@gmail.com

Citation: Grohs MA (2018) Uterine Apoplexy. *Int J Clin Med Imaging* 5: 609. doi:[10.4172/2376-0249.1000609](https://doi.org/10.4172/2376-0249.1000609)

Copyright: © 2018 Grohs MA. This is an open-access article distributed under the terms of the Creative Commons Attribution License, which permits unrestricted use, distribution, and reproduction in any medium, provided the original author and source are credited.
