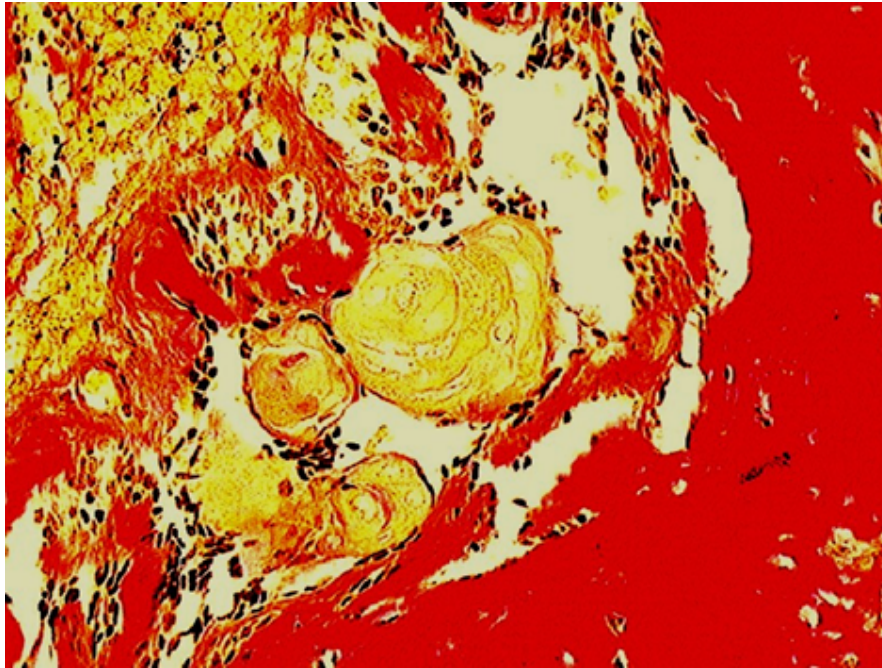


## Clinical Image

### **Title: Van Gieson stain for Odontogenic Tumor**

**Treville Pereira and D.Y.Patil**

*Dental College & Hospital Nerul Navi Mumbai, India*



Ameloblastomas do not generally show evidence of induction; however rare cases associated with odontome have been reported and are referred to as ontoameloblastoma. This image presents an unusual case of ameloblastoma with evidence of induction of dentinoid by tumor cells but without concomitant formation of enamel along with features of ghost cells.