

Clinical-Medical Image

Vocal Fold Paralysis from Recurrent Laryngeal Nerve Compression

Sabin Kshattry*

Department of Internal Medicine, Yale New Haven Hospital, New Haven, Connecticut, USA

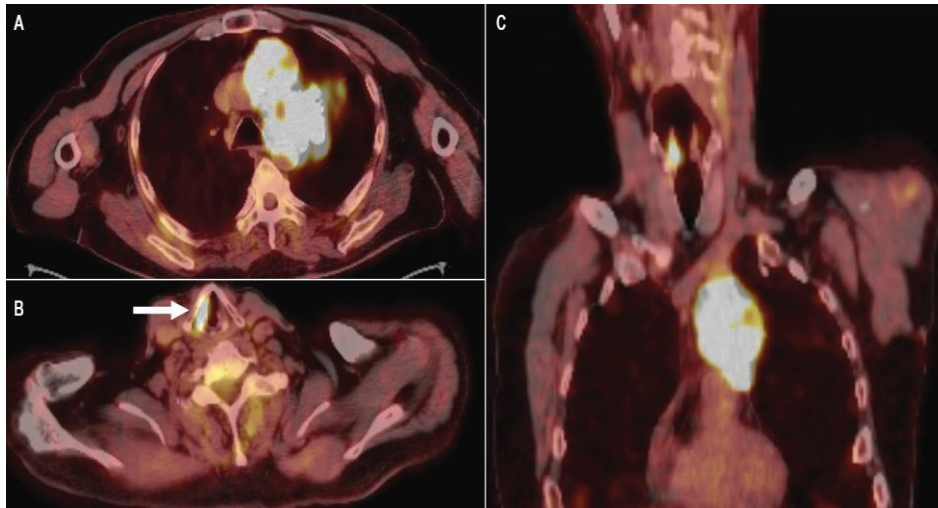


Figure 1: PET/CT of the patient showing an FDG-avid mass in the left upper lobe (panel A), and an asymmetric FDG uptake within the right vocal fold (panels B and C).

Clinical Image

A 63-year-old man with a recently diagnosed squamous cell cancer of the left lung was brought to the hospital by his wife due to a 2-week history of progressive altered mental status and a few months of hoarseness. Laboratory studies showed a calcium level of 14.4 mg per deciliter (reference range, 8.5 to 10.5). After treatment with intravenous fluids, calcitonin, and zoledronate, his serum calcium normalized after about three days and mental status improved back to baseline. Positron emission tomography with 2-deoxy-2-[18F] fluoro-D-glucose integrated with computed tomography (18F-FDG PET/CT) showed a large FDG-avid mass in the left upper lobe involving the left hilum and left prevascular region (Panel A), and also an asymmetrically increased FDG uptake within the right vocal fold (Panel B, arrow; Panel C) (Figure 1) likely secondary to left vocal fold paralysis from left recurrent laryngeal nerve compression. Bedside flexible laryngoscopy was consistent with left vocal fold paralysis fixed in the medial position. He was discharged with outpatient plans for chemotherapy initiation, and injection laryngoplasty for a stronger cough, voice restoration, and airway protection. However, his hypercalcemia progressively became refractory to calcitonin, bisphosphonates and denosumab delaying chemotherapy as well as his laryngoplasty. He started radiation therapy in the interim, but ultimately succumbed to the disease three months later.

Declaration of Interests

The authors declare that they have no competing interests.

*Corresponding author: Sabin Kshattry, Internal Medicine, Yale New Haven Hospital, New Haven, Connecticut, USA, E-mail: sabin.kshattry@yale.edu

Citation: Kshattry S (2021) Vocal Fold Paralysis from Recurrent Laryngeal Nerve Compression. *Int J Clin Med Imaging* 8:782

Copyright: © 2021 Kshattry S. This is an open-access article distributed under the terms of the Creative Commons Attribution License, which permits unrestricted use, distribution, and reproduction in any medium, provided the original author and source are credited.