

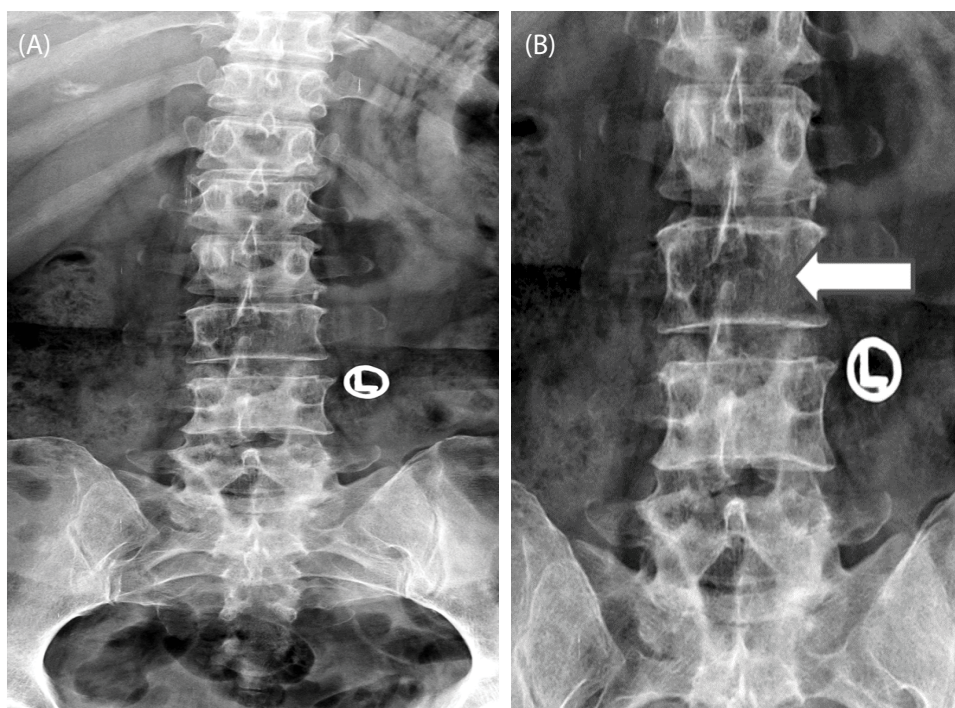
Case Blog

Title: Winking-owl Sign - An Uncommon Presentation of Spine Metastasis

Rajul Rastogi^{1*}, Sujeet Jain², Pawan Joon¹, Yuktika Gupta¹, Asif Majid Wani¹ and Vijai Pratap¹

¹Teerthanker Mahaveer Medical College and Research Center, Moradabad, U.P., India

²School of Medical Science and Research, Greater Noida, U.P., India



Figures 1A and 1B: Radiographs of DL spine in AP projection (1b- magnified image) shows nonvisualisation of left pedicle of L3 vertebra along with signs of spondylotic changes an osteoporosis.

Keywords: Winking; Spine; Radiograph

Introduction

Spinal metastasis is the commonest form of secondary osseous involvement by variety of cancers usually presenting clinically in the form of backache. They may be osteolytic, osteoblastic or mixed types. Spinal radiograph is usually the first investigation used to define the future course of action.

Case Presentation

A 50-year old female from a nearby village came to outpatient department of our hospital with an acute history of severe backache since few days. Clinical examination revealed focal tenderness in mid-lumbar region. Laboratory investigations were however, unremarkable. She was advised radiograph of dorsolumbar spine region in anteroposterior and lateral projections. Careful evaluation of radiographs revealed nonvisualisation of left-sided pedicle of L3 vertebra representing winking-owl sign, conspicuously noted on anteroposterior projection associated with surrounding vertebral lucency (Figures 1A and 1B). There was associated early lumbar spondylotic changes and diffuse osteopenia as well. Based on radiological findings, the diagnosis of solitary vertebral metastasis was kept as the first differential diagnosis and further work-up was advised to search for the primary tumour. A thorough clinical history and examination revealed invasive breast carcinoma with history of occasional blood stains on clothes and metastases to lungs on chest radiograph. Histopathological examination confirmed the primary malignancy and metastases. Patient was referred to higher center for further management.

*Corresponding author: Rajul Rastogi, Department of Radiodiagnosis, Teerthanker Mahaveer Medical College and Research Center, Moradabad, U.P., 244001, India
E-mail: eesharastogi@gmail.com

Copyright: © 2016 Rastogi R, et al. This is an open-access article distributed under the terms of the Creative Commons Attribution License, which permits unrestricted use, distribution, and reproduction in any medium, provided the original author and source are credited.

Discussion

All types of spinal metastases are usually multiple at the time of presentation, but occasionally they may be solitary at first presentation. Detecting solitary metastasis is important in a patient with known primary malignancy as it predicts progression of disease, poorer prognosis and requires further intervention in the form of chemotherapy or radiotherapy depending on the sensitivity of the primary tumour. At time, solitary metastasis may be the first presentation of cancer thus making aggressive search for primary tumour very imperative for deciding future course of action as seen in our index case. Pedicle destruction of a vertebra is an important radiographically detectable signs of osteolytic metastasis especially carcinoma. Though any part of the neural arch of vertebra may be involved by metastases yet the vertebral pedicle is the commonest site. Involvement of pedicle with adjacent part of posterior vertebral body results in loss of cortical margins that can be detected radiographically as nonvisualisation of vertebral pedicle on anteroposterior radiograph [1]. This is described as one-eyed pedicle or winking-owl sign. It is most commonly noted in the lower dorsal and lumbar vertebrae with solitary involvement being commoner than the multifocal involvement. Rarely both the pedicles may be involved by the above process leading to nonvisualisation of both vertebral pedicles on anteroposterior radiograph resulting in blind-vertebra [1,2]. Differential diagnosis includes congenital absence of pedicle which is usually associated with hypoplastic /agenetic ipsilateral and hyperplastic contralateral pedicles. There may be some degree of abnormal spinal curvature as well. Congenital disease usually presents in early childhood/adolescence. To summarise, it is important to recognise solitary spinal metastasis in form of winking-owl sign on spine radiograph as it affects the prognosis of the patient suffering from the cancers.

References

1. Algra PR, Heimans JJ, Valk J, Nauta J, Lachniet M, et al. (1992) Do metastases being in the body or the pedicles? Imaging study in 45 patients. *AJR* 158: 1275-1279.
2. Yochum TR, Rowe LJ (2005) Tumor and Tumor-like processes. Yochum and Rowe's Essentials of Skeletal Radiology (3rd edn.) Lippincott Williams & Wilkins 1148-1152.