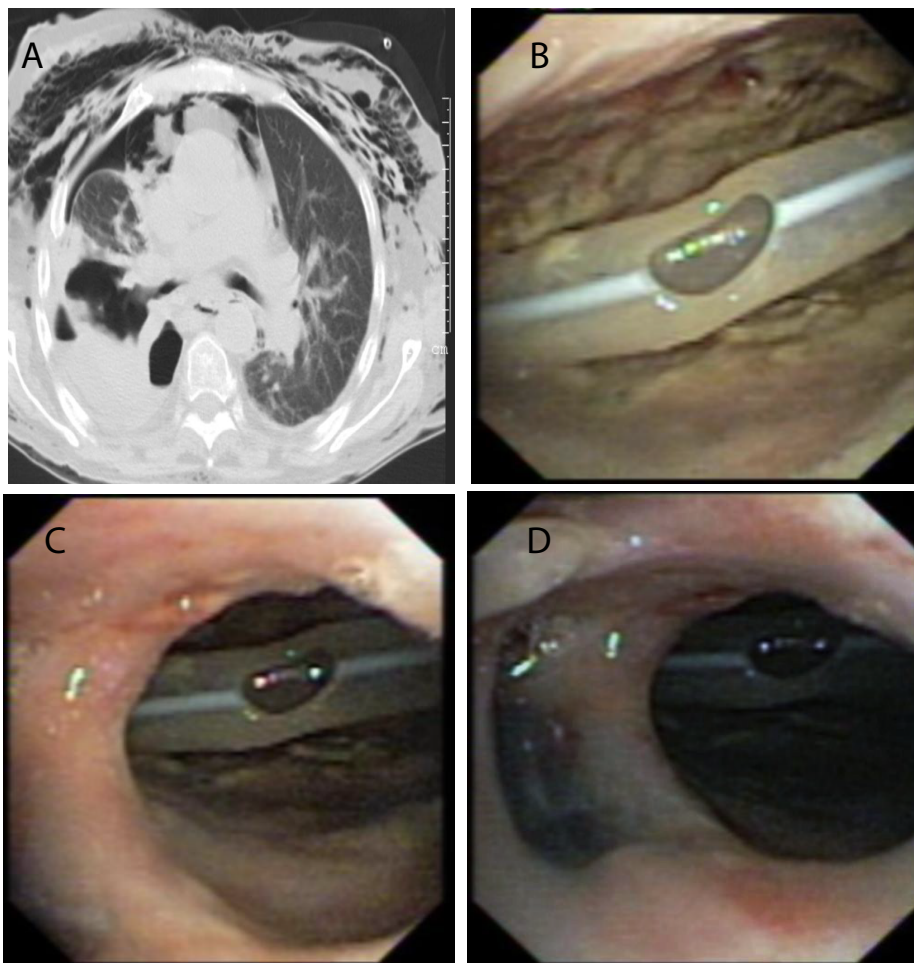


Clinical Image

Title : Rheumatoid Arthritis Under Corticosteroid Therapy

Inês Neves¹, Adriana Magalhães¹

¹Pulmonology Department, Hospital de São João; Faculty of Medicine of Porto University; Centro Hospitalar de São João, Porto Portugal.



A 66 year-old female patient, with a history of rheumatoid arthritis under corticosteroid therapy, was admitted to the Pulmonology ward with cavitated pulmonary tuberculosis and a pneumothorax, with high flow bronchopleural air leak. Chest CT revealed pneumomediastinum, loculated right pneumothorax, and a communication, 48X32 cm, between the superior lobar bronchus and a parenchymal cavitation, communicating with the pleural space (Panel A). Fiberoptic bronchoscopy showed a huge hole at the entrance of the posterior segment of the right upper lobar bronchus (Panel B and Panel C), through which it was possible to pass the fiber-bronchoscope and visualize the chest tube inside the pleural cavity (Panel D). She had no had medical conditions to thoracic surgical intervention, and after 90 days of anti-tuberculosis treatment and thoracic drainage, there was a spontaneous cicatrization of the fistula.