

Clinical Image

A Classical Image of Dermographism

Atoka Sumi¹, Ojing Komut², Taso Beyong³, Tony Ete⁴, Jaya Mishra^{5*} and Animesh Mishra⁴

¹Department of Dermatology, Apex Hospital, Dimapur, Nagaland, India

²Department of Surgery, North Eastern Indira Gandhi Regional Institute of Health and Medical Sciences, Mawdiangdiang, Shillong, India

³Department of General Medicine, North Eastern Indira Gandhi Regional Institute of Health and Medical Sciences, Mawdiangdiang, Shillong, India

⁴Department of Cardiology, North Eastern Indira Gandhi Regional Institute of Health and Medical Sciences, Mawdiangdiang, Shillong, India

⁵Department of Pathology, North Eastern Indira Gandhi Regional Institute of Health and Medical Sciences, Mawdiangdiang, Shillong, India

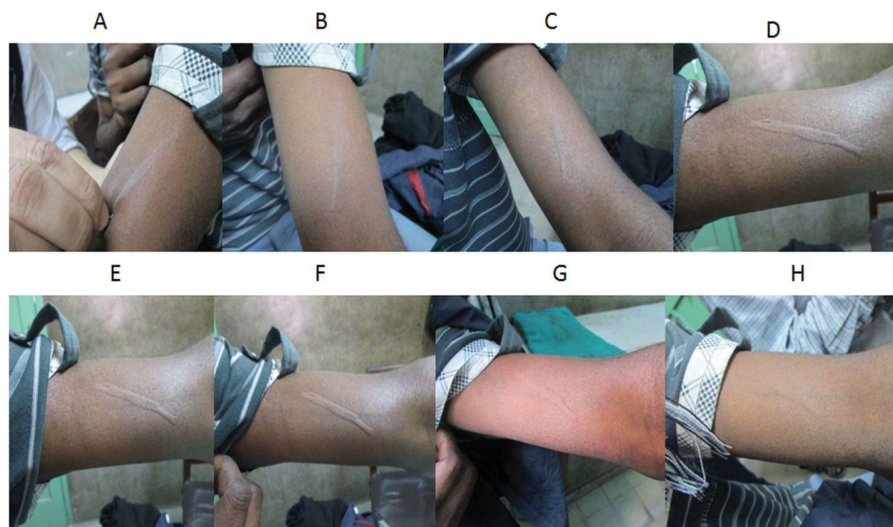


Figure 1: Demonstration of raised skin surface on left arm following scratch with a pin head (Panel A-G).

Clinical Image

A 31-year-old male presented with a complaint of itching followed by localized swelling of the part that has been scratched. He also complained of swelling of parts of limb and back on being held tightly, stroked or rubbed and intermittent swelling of lips. The symptom was worsened by abrasive and tight clothing. The patient had no history of respiratory symptoms suggestive of asthma. General survey and systemic examination was normal other than raised skin within minutes on scratching left arm with a pinhead suggestive of dermographism (Panel A-G). Routine blood count revealed haemoglobin 13 gm/dl, a leucocyte count of 8000/cumm with increase in the percentage of eosinophils. The absolute eosinophil count was 880/cumm. Serum IgE level was 835 IU/ml. The patient was treated with albendazole (400 mg), levocetirizine (5 mg) for four weeks and with a H2 receptor antagonist with an advice to follow after one month.

*Corresponding author: Jaya Mishra, Department of Pathology, North Eastern Indira Gandhi Regional Institute of Health and Medical Sciences, Mawdiangdiang, Shillong, India, Tel: +91-96824331357; E-mail: drjayamshillong@gmail.com

Citation: Sumi A, Komut O, Beyong T, Ete T, Mishra J, et al. (2017) A Classical Image of Dermographism. *Int J Clin Med Imaging* 4: 584. doi:10.4172/2376-0249.1000584

Copyright: © 2017 Sumi A, et al. This is an open-access article distributed under the terms of the Creative Commons Attribution License, which permits unrestricted use, distribution, and reproduction in any medium, provided the original author and source are credited.