

Clinical-Medical Image

A Disconcerting Case of a Nodular Hidradenoma of the Scalp Simulating a Basal Cell Carcinoma

Ihsane Hallab

Department of Radiology, Oncology National Institute, Rabat, Morocco

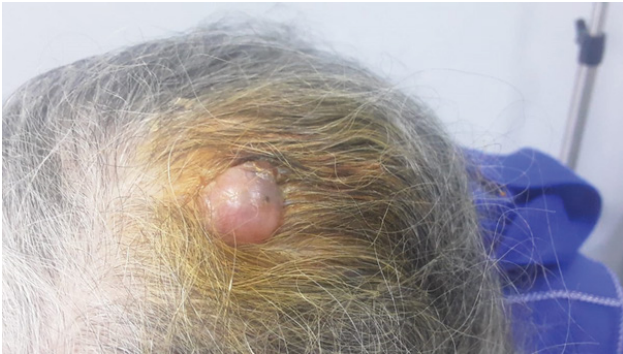


Figure 1: Protruding erythematous nodule in the scalp.

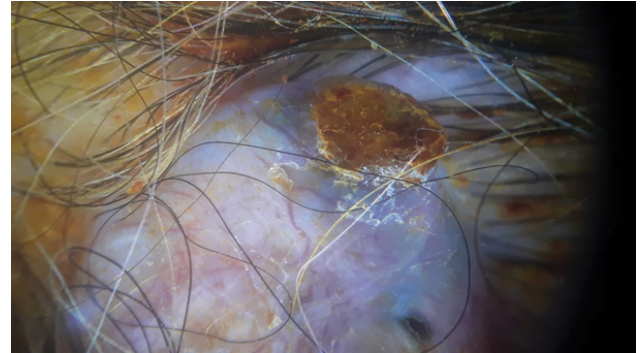


Figure 2: Dermoscopic appearance suggestive of basal cell carcinoma.

Clinical Image

The patient is an 82-year-old female with no significant medical history who presented for evaluation for a bleeding scalp nodule. It appeared 6 months ago as a papule, asymptomatic. Physical examination showed a large nodule, measuring 2 cm × 2 cm × 2 cm in diameter, warm, painful and firm on palpation, letting pus weld (Figure 1).

The dermoscope revealed an absence of a pigmented network, a tree trunk vascularization, blue gray blood cells, which led us to basal cell carcinoma (Figure 2).

The patient underwent surgical excision with healthy skin margins of 0.5 cm. Histology returned in favour of a benign hidradenoma with no signs of malignancy.

Directed healing was used rather than skin grafting with good progress under alginate dressings

Keywords: Hidradenoma; Dermoscope

Declaration of Interests

The authors declare that they have no competing interests.

*Corresponding author: Ihsane Hallab, Department of Radiology, Oncology National Institute, Rabat, Morocco; E-mail: drihsane13@gmail.com

Citation: Hallab I (2021) A Disconcerting Case of a Nodular Hidradenoma of the Scalp Simulating a Basal Cell Carcinoma. *Int J Clin Med Imaging* 8:791.

Copyright: © 2021 Hallab I. This is an open-access article distributed under the terms of the Creative Commons Attribution License, which permits unrestricted use, distribution, and reproduction in any medium, provided the original author and source are credited.
