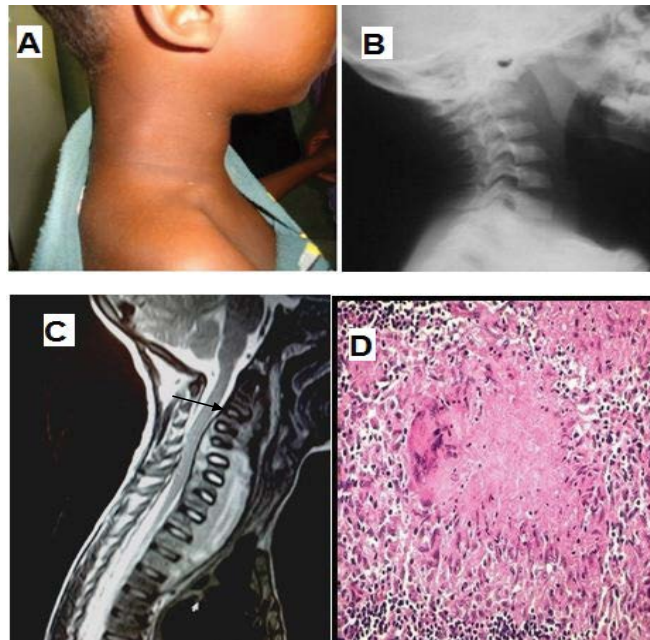


## Clinical Image

### Title: A Rare Cause of Retropharyngeal Abscess: Cervical Pott's disease

Awad Ali M. Alawad<sup>1\*</sup> and Amr F.M. Khalifa<sup>2</sup>

Department of Surgery, University of Medical sciences and Technology, Sudan  
Department of Otolaryngology, Khartoum ENT Teaching Hospital, Sudan



A 6-year-old boy presented with 4 months of right neck pain that, along with increasing swelling over the previous 15 days, was associated with fever, night sweats, and dysphagia. Physical examination showed diffuse right neck swelling (Figure 1A). Serological tests for HIV were negative. A lateral cervical spine X-ray revealed widening of the retropharyngeal space (Figure 1B). Magnetic resonance imaging revealed a hyperintense prevertebral collection (Figure 1C). A percutaneous fine needle aspiration decompressed the collection. Microscopic examination of the material obtained showed acid fast bacilli and granulomatous inflammation (Figure 1D). Administration of antituberculous drugs (isoniazid, rifampicin, pyrazinamide) led to rapid improvement (disappearing of visible swelling at 4 weeks) especially the ability to eat normally. Six months of treatment was completed. Retropharyngeal abscess due to cervical Pott's Disease is rare and should be suspected with a destructive spine lesion with associated findings in the appropriate setting [1,2].

Figure 1: (A) Neck swelling and stiffness observed on the right side. (B) A lateral cervical X-ray demonstrated widening of the retropharyngeal space. (C) Magnetic resonance imaging (MRI) revealed a decrease in vertebral body height, irregular margins, and decrease in intravertebral disk space at C3-C4 and destroyed C1 vertebra (marked by the black arrow). (D) Photomicrograph revealed caseating granuloma with central necrosis, lymphocytes, and giant cells, consistent with tuberculosis

#### References

1. Diom ES, Ndiaye C, Djafarou AB, Ndiaye IC, Faye PM, et al. (2011) A case of cervical Pott's disease revealed by parapharyngeal abscess. *Eur Ann Otorhinolaryngol Head Neck Dis* 128: 151-153.
2. Attia M, Harnof S, Knoller N, Shacked I, Zibly Z, et al. (2004): Cervical Pott's disease presenting as a retropharyngeal abscess. *Isr Med Assoc J* 6: 438-439.