

Clinica-Medical Image

Acute Eosinophilic Pneumonia Due To Cocaine Inhalation

Mustafa Ozgur Cirk¹, Oral Mentese¹, Meric Unver¹, Ali Alagoz¹ and Sema Avci^{2*}

¹Ankara Ataturk Chest Diseases and Chest Surgery Research and Training Hospital, Ankara, Turkey

²Sabuncuoglu Serefeddin Research and Training Hospital, Amasya University, Amasya, Turkey

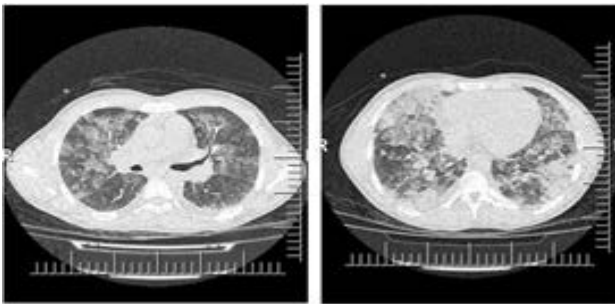


Figure 1: Pretreatment images.

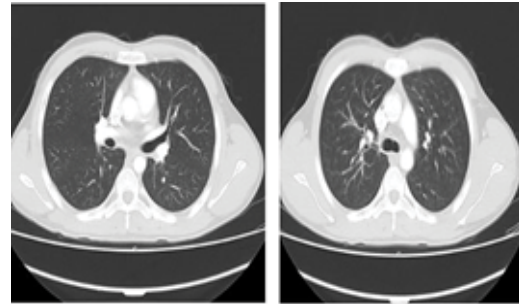


Figure 2: Complete healing was shown on chest tomography

Keywords: Eosinophilic pneumonia; Cocaine inhalation; Intensive care

Introduction

Acute eosinophilic pneumonia is an uncommon serious and rapidly progressive lung disease and it can cause mortal respiratory failure. The cause of this acute respiratory distress syndrome are smoking, medications, infections, inhalational exposures to drugs or dusts and idiopathic. Airway epithelial injury, endothelial injury, releasing of interleukin-33, eosinophilic infiltration, degranulation and lung inflammation are mechanisms of this acute respiratory syndrome. Acute eosinophilic pneumonia is diagnosed with following combination of clinical and radiological findings; fever of less than five days' duration, hypoxemia, diffuse alveolar-interstitial opacities on chest graphy, bronchoalveolar lavage fluid consisting of >25% eosinophils, rapid response to corticosteroids and absence of parasitic, fungal, or other infections. Herein, we aimed to present a clinical image of 21-year-old male patient diagnosed with acute eosinophilic pneumonia due to cocaine inhalation.

Case

A 21-year-old male patient admitted to emergency room with complaints of progressive dyspnea, cough, sputum and hemoptysis. The patient did not have chronic disease or medical drug history. He has been smoking for five years. It was learned that he inhaled cocaine about 48 hours ago before the admission. On physical examination, bilateral decreased respiratory sounds, sibilant bronchus and bilateral basal rales were revealed. The vital signs of patients were following; tension arterial 110/70 mmHg, fever 38.1°C, respiratory rate 31 per minute, heart rate 115 per minute and oxygen saturation on room air 65%. The arterial blood gas analysis was; pH 7.38, pO₂ 30 mmHg, pCO₂ 42 mmHg and SpO₂ 62 mmHg. The complete blood count analysis was; white blood cell 22.16 (1000 μ L), eosinophil blood (%) 1.21 (normal range 0-0.7) and neutrophil count 18.6 (1000 μ L). The other blood parameters were normal. The culture in throat swab specimens was negative.

Chest computed tomography of the patient demonstrated diffuse ground glass opacities and minimal pleural fluid in the right hemithorax (Figure 1). The patient was hospitalized to the intensive care unit. On fiberoptic bronchoscopy, the mucosa was hyperemic, edematous and fragile. The cell counts from bronchoalveolar lavage revealed more than 25% eosinophils. The clinical

*Corresponding author: Sema Avci, Sabuncuoglu Serefeddin Research and Training Hospital, Amasya University, Amasya, Turkey, E-mail: dr.semaavci@outlook.com

Citation: Cirk MO, Mentese O, Unver M, Alagoz A, Avci S (2019) Acute Eosinophilic Pneumonia Due To Cocaine Inhalation. *Int J Clin Med Imaging* 6: 656.

Copyright: © 2019 Cirk MO, et al. This is an open-access article distributed under the terms of the Creative Commons Attribution License, which permits unrestricted use, distribution, and reproduction in any medium, provided the original author and source are credited.

diagnosis of the patient was acute eosinophilic pneumonia and intravenous 2 mg/kg/day corticosteroid treatment was started. On the 10th day, complete improvement was shown on chest tomography (Figure 2). The patient's clinical findings started to regress and he was discharged on the 11th day.