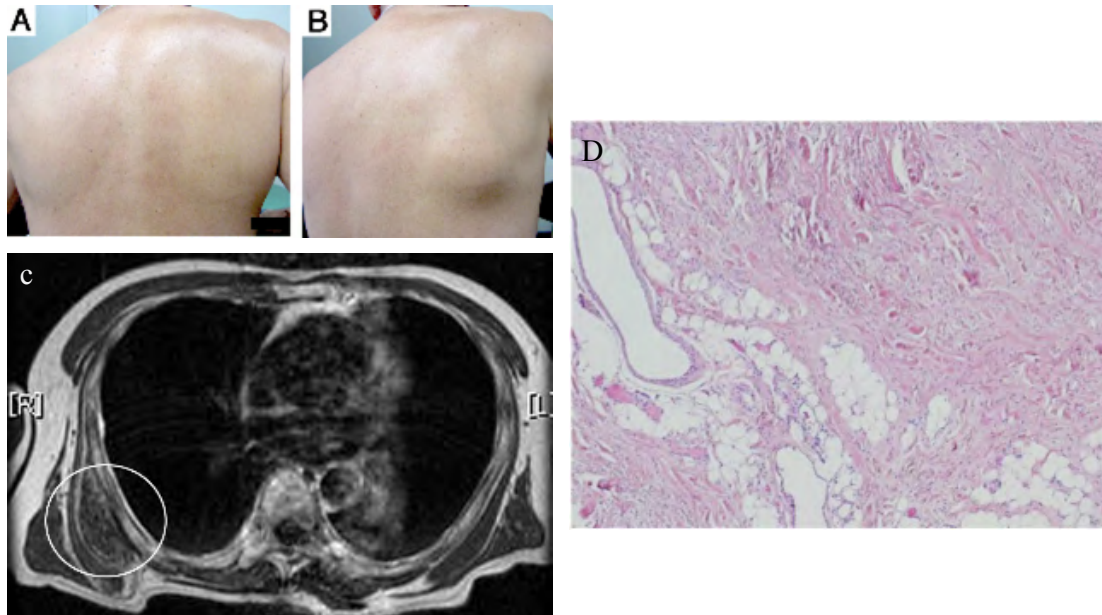


Clinical Image

Elastofibroma Dorsi: A Subscapular Mass Appearing or Disappearing with Shoulder Motion

Teruo Iwasaki*, Chihyon Son and Yoshio Yamasaki

Department of Surgery, Japan Community Healthcare Organization (JCHO), Osaka Hospital, Fukushima-ku, Osaka, Japan



Figures A and B: Appearance of the right subscapular region with the right shoulder and arm in the neutral position (A) and on horizontal adduction of the right shoulder (B).

Figure C: Magnetic resonance image (T1-weighted), transverse section. A mass is located under the right scapula (circle).

Figure D: Hematoxylin and eosin staining with 40-fold magnification.

A 65-year-old man presented with a right subscapular mass with discomfort, snapping of the scapula and restriction of shoulder motion on the right side. His hobby was playing golf. He underwent left lobectomy for goiter at 34 years of age. On physical examination, with shoulder and arm in the neutral position, a projecting inferior scapula was normal (Figure A). On horizontal adduction of the right shoulder, a fist-sized mass appeared in the subscapular region (Figure B). Laboratory findings were unremarkable. Computed tomography revealed an approximately 8 cm heterogeneous soft-tissue mass in the infrascapular region. Magnetic resonance imaging showed a mass, which was isointense to skeletal muscle and contained uniform signals similar to adipose tissue (Figure C). The tumor was diagnosed as elastofibroma dorsi. Complete excision was indicated due to his symptom and the tumor size. Microscopically, the tumor was composed of eosinophilic dense collagen fiber bundles and elastic fibers, consistent with elastofibroma dorsi (Figure D). Postoperative course was uneventful, and no recurrence was found at 30 months after surgery. Elastofibroma dorsi is an uncommon benign soft tissue tumor with a characteristic location and imaging appearance [1, 2]. Professionals of clinical and medical fields should consider this condition in the differential diagnosis of a subscapular mass.

References

1. Schafmayer C, Kahlke V, Leuschner I, Pai M, Tepel J (2006) Elastofibroma dorsi as differential diagnosis in tumors of the thoracic wall. *Ann Thorac Surg* 82: 1501-1504.
2. Lococo F, Cesario A, Mattei F, Petrone G, Vita LM, et al. (2013) Elastofibroma dorsi: clinicopathological analysis of 71 cases. *Thorac Cardiovasc Surg* 61: 215-222.

*Corresponding author: Teruo Iwasaki, Department of Surgery, Japan Community Healthcare Organization (JCHO), Osaka Hospital, 4-2-78 Fukushima, Fukushima-ku, Osaka, 553-0003, Japan, Tel: +81-6-6441-5451; Fax: +81-6-6445-8900; e-mail: teruteruah@m4.dion.ne.jp

Citation: Iwasaki T, Son C, Yamasaki Y (2016) Elastofibroma Dorsi: A Subscapular Mass Appearing or Disappearing with Shoulder Motion. *Int J Clin Med Imaging* 3: 494. doi:10.4172/2376-0249.1000494

Copyright: © 2016 Iwasaki T, et al. This is an open-access article distributed under the terms of the Creative Commons Attribution License, which permits unrestricted use, distribution, and reproduction in any medium, provided the original author and source are credited.