

Clinical-Medical Image

## Frontal Horn: A Cutaneous Squamous-Cell Carcinoma of the Forehead Area

Francesca Antonella Bianchi and Marco Bernardi

Department of Surgical Sciences, Maxillofacial Surgery Section, Santa Croce and Carle Hospital Districts, Cuneo, Italy

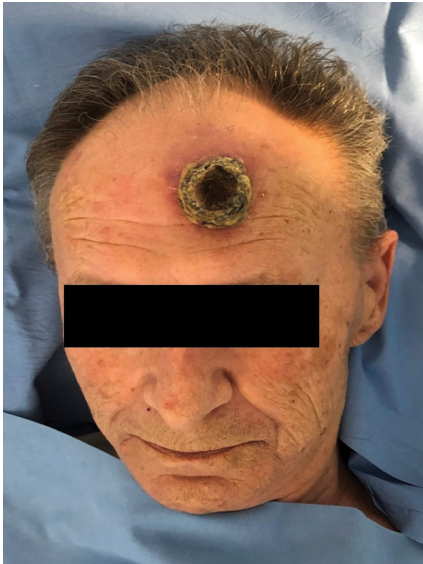

Figure 1: Physical appearance of the patient front view.

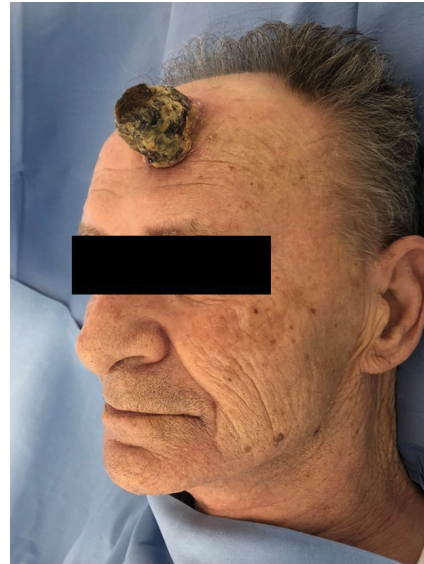

Figure 2: Physical appearance of the patient side view.

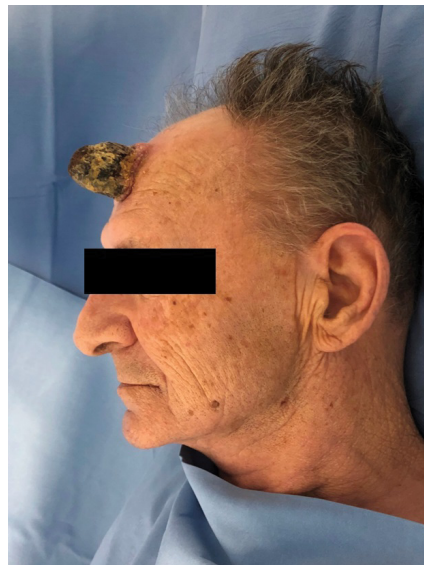


Figure 3: Physical appearance of the patient left view.

### Clinical Image

An 83-year-old man presented with a voluminous exophytic lesion on forehead that had been quickly increasing in size during the past 3 months. The lesion had become progressively corneous, with intermittent bleeding.

\*Corresponding author: Francesca Antonella Bianchi, MD PhD, Santa Croce and Carle Hospital Districts Via Michele Coppino 26, 12100, Cuneo, Italy, Tel: +0171 642254; E-mail: francescaantonella.bianchi@gmail.com

Citation: Bianchi FA and Bernardi M (2021) Frontal Horn: A Cutaneous Squamous-Cell Carcinoma of the Forehead Area. *Int J Clin Med Imaging* 8:790.

Copyright: © 2021 Bianchi FA, et al. This is an open-access article distributed under the terms of the Creative Commons Attribution License, which permits unrestricted use, distribution, and reproduction in any medium, provided the original author and source are credited.

The physical examination revealed a well-defined frontal horn measuring 5 × 3 cm in diameter (Figures 1-3).

A Cutaneous Squamous Cell Carcinoma (CSCC) was identified on biopsy.

Unfortunately the patient had a heart attack and he was hospitalized in a cardiac care unit for a month.

When the general conditions allowed a general anaesthesia the patient underwent a surgical debulking of the lesion but he died before starting oncological therapy from complications of cardiovascular disease.

CSCC arises from the malignant proliferation of epidermal keratinocytes. It is the second most common cause of death from skin cancer after melanoma; its incidence continues to rise and is an underestimate [1-3].

**Keywords:** Frontal Horn; Carcinoma

#### **Declaration of Interests**

The authors declare that they have no competing interests.

#### **References**

- [1] Alam M, Ratner D (2001) Cutaneous squamous-cell carcinoma. *NEJM* 344:975-983.
- [2] Rogers HW, Weinstock MA, Feldman SR, Coldiron BM (2015) Incidence estimate of non-melanoma skin cancer (keratinocyte carcinomas) in the US population 2012. *JAMA Derm* 151:1081-1086.
- [3] Brougham ND, Tan ST (2014) The incidence and risk factors of metastasis for cutaneous squamous cell carcinoma-implications on the T-classification system. *J Surg Oncol* 110: 876-882.