

Case Blog

Title: Gallbladder Volvulus: A Rare Emergent Cause of Acute Cholecystitis, if Untreated, Progresses to Necrosis and Perforation

Justin L. Regner* and Angela Lomas

Department of Surgery, Baylor Scott and White Health and Texas A&M Health Science Center College of Medicine, Temple, TX, USA

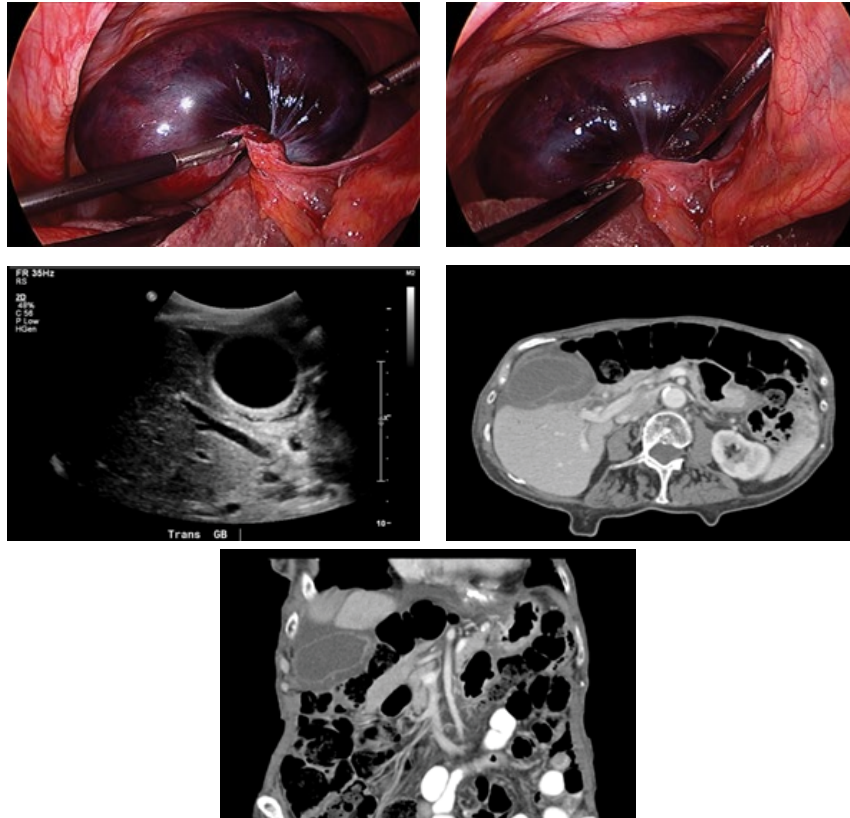


Figure 1: The gallbladder (black in color) volvulized on its pedicle is necrotic in appearance.

Figure 2: A different angle of the gallbladder with less manipulation reveals the extent of the torsion and the significant pedunculated origin.

Figure 3: Ultrasound imaging revealed gallbladder wall thickening of 5 mm and pericholecystic fluid consistent with acute cholecystitis.

Figure 4: Computed tomography axial cross section depicts a dilated gallbladder with wall thickening and pericholecystic fluid present.

Figure 5: A coronal cross section CT image reveals the extent of the gallbladder dilation and amount of pericholecystic fluid.

Case Presentation

An 86 year-old woman with a past medical history significant for abdominal hernia and Alzheimer dementia presented to the Emergency Department with a 24 hour history of acute right upper quadrant pain associated with nausea and non-bilious emesis. Physical exam revealed right sided abdominal tenderness with associated mass. All laboratory values were within normal ranges. Both abdominal ultrasound and computed tomography of the abdomen/pelvis revealed a large distended gallbladder with wall thickening and gallstones. Based on presentation and radiologic findings, the emergency general surgery service was consulted for suspected acute cholecystitis. The patient was then admitted for intravenous antibiotics and scheduled for laparoscopic cholecystectomy the following day. Intra-operative findings revealed volvulus with acute necrosis of the entire gallbladder. The gallbladder had a long pedunculated cystic duct and artery that was detorsed before proceeding with resection. Postoperatively, the patient did well and was discharged a few days later tolerating a regular diet.

Gallbladder volvulus, a rare occurrence, is the result of a free “floating gallbladder” or gallbladder with a long cystic duct which rotates on its axis [1]. The literature reports approximately 500 cases, with the majority diagnosed intra-operatively [2]. However, current literature suggests that a “typical whirl” sign can diagnose the disease entity through imaging [3]. This torsion, if untreated

*Corresponding author: Justin L. Regner, Department of Surgery, Baylor Scott & White Health, 2401 South, 31st Street, Temple, Texas, USA; Tel: (254) 724-7017; Fax: (254) 724-7489; E-mail: Justin.Regner@BSWHealth.org

Copyright: © 2016 Regner JL Lomas A. This is an open-access article distributed under the terms of the Creative Commons Attribution License, which permits unrestricted use, distribution, and reproduction in any medium, provided the original author and source are credited.

emergently, has a high mortality rate due to the sequelae of gangrene and perforation. Our case was initially diagnosed based on presentation and radiologic examination as “typical” acute cholecystitis (Figures 1-5). This misdiagnosis triaged our patient into an urgent but not emergent status, and delayed operation 24 hours. In retrospect, we believe that if the patient had presented with signs of sepsis or decompensated after admission, we would have performed an emergent cholecystectomy owing to the complications of gangrene or perforation as high risk for morbidity and mortality [2].

References

1. Pottorf BJ, Alfaro L, Hollis HW (2013) A Clinician's Guide to the Diagnosis and Management of Gallbladder Volvulus. *Perm J* 17: 80-83.
2. Vedanayagam MS, Nikolopoulos I, Janakan G, El-gaddal A (2013) Gallbladder volvulus: a case of mimicry. *BMJ Case Rep*.
3. Gog A, Robert B, Mouly C, Castier M, Chivot C, et al. (2013) Gallbladder volvulus: a rare case of acute cholecystitis. *Diagn Interv Imaging* 94: 893-895.