

Clinica-Medical Image

Huge Ovarian Borderline Mucinous Cystadenoma

Pei-Hung Liao*

Department of Emergency Medicine, Tung's Taichung Metro Harbor Hospital, Taiwan, P.R. China

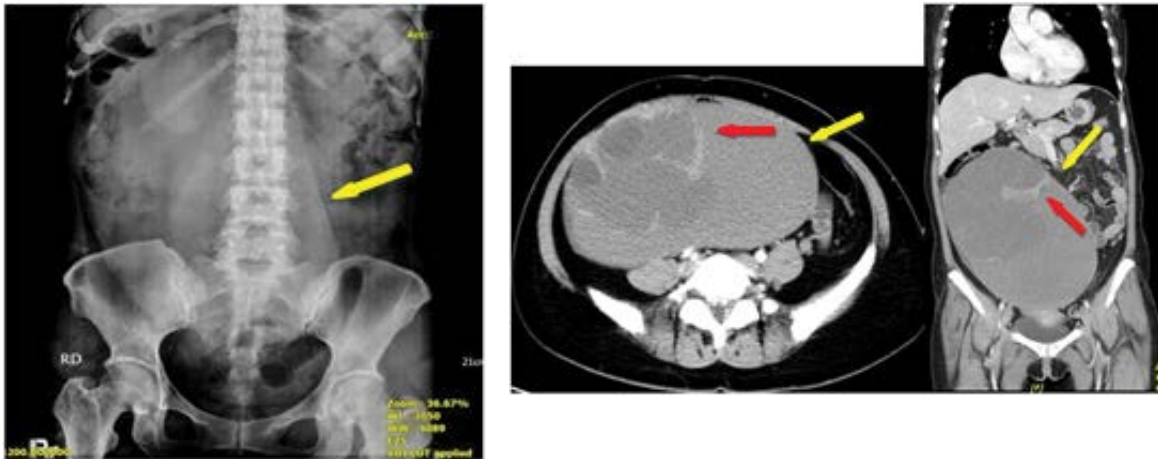


Figure 1: A hug soft tissue density (yellow arrow) in right abdomen and pelvis with extrinsic displacement of bowel roop and right kidney.

Figure 2: A huge cystic tumor (yellow arrow) in pelvis and abdomen cavity has enhanced solid component (red arrow) with different density of cystic content.

Clinical Image

This 46-year-old woman without any systemic disease, she was brought to the ED because of acute right lower abdominal pain for about 2 days. Physical exams showed localized tenderness with muscle guarding over right lower abdomen. KUB revealed a huge soft tissue density in right abdomen and pelvis. Whole abdomen computed tomography revealed a huge cystic tumor (about 25.0 cm × 20.3 cm × 11.5 cm) in pelvis and abdomen cavity with enhanced solid component. She was admitted and for laparotomy, surgical pathologic examination revealed mucinous borderline tumor with focal atypia and extensive necrosis. After surgery, patient's condition was stable and she was discharged after 7-days admission. Ovarian borderline mucinous cystadenoma are difficult to detect until in advanced size. Most common symptoms are abdominal distention, abdominal pain and even palpable mass, but some patients are asymptomatic. The major complications are torsion and rupture. The golden t gold standard treatment is surgical removal the tumor. A 10-year survival rate for mucinous tumors is excellent without invasion, but is highly dependent on stage and histologic composition (Figures 1 and 2).

*Corresponding author: Pei-Hung Liao, Consultant, Department of Emergency Medicine, Tung's Taichung Metro Harbor Hospital, Taiwan, P.R. China, E-mail: alecstar@mail2000.com.tw

Citation: Liao PH (2019) Huge Ovarian Borderline Mucinous Cystadenoma. *Int J Clin Med Imaging* 6: 659.

Copyright: © 2019 Liao PH. This is an open-access article distributed under the terms of the Creative Commons Attribution License, which permits unrestricted use, distribution, and reproduction in any medium, provided the original author and source are credited.