

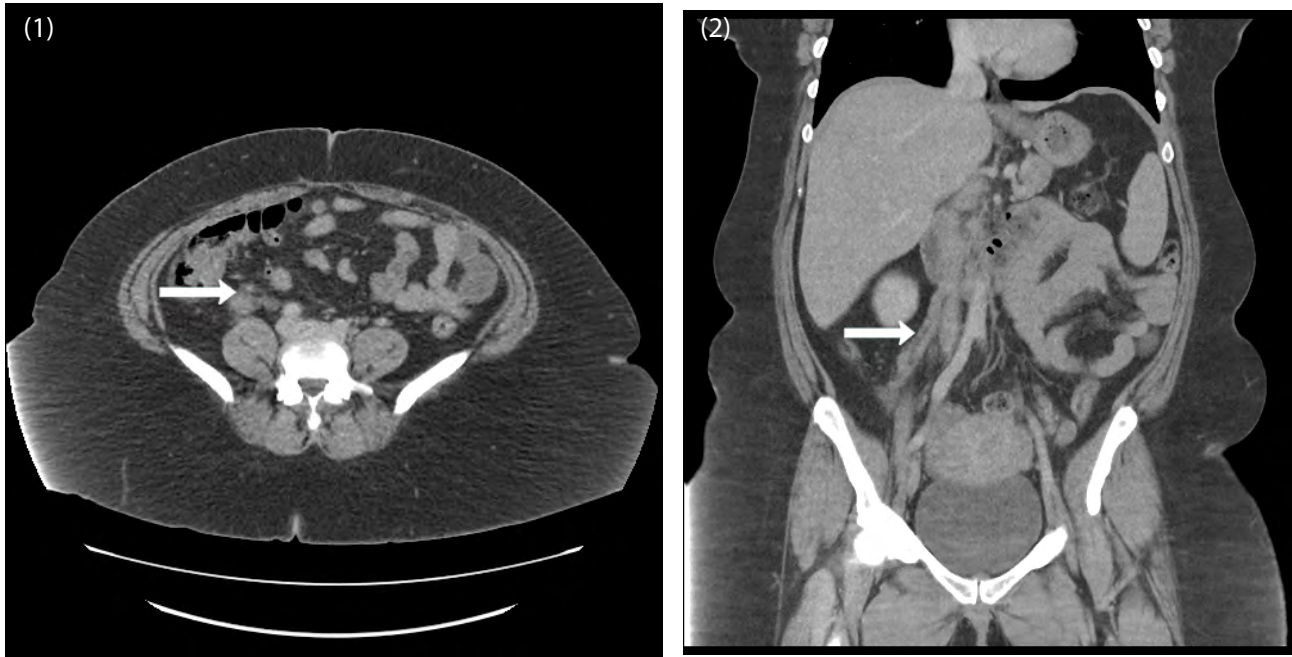
Medical Image

## Idiopathic Ovarian Vein Thrombosis in a Healthy Individual

Namratha Kodali<sup>1\*</sup> and Kit Lu<sup>2</sup>

<sup>1</sup>Department of Internal Medicine, Pinnacle Health Hospital, Harrisburg, Pennsylvania, United States

<sup>2</sup>Department of Hematology and Oncology, Pinnacle Health Hospital, Harrisburg, Pennsylvania, United States



**Figure 1:** Axial section with arrow pointing to thrombosed vein.  
**Figure 2:** Coronal section.

A 40 year old premenopausal female presented with right lower quadrant abdominal pain of 2 days duration. She denied any recent history of pregnancy, abdominal wall surgeries or use of oral contraceptive pills. She has no personal or family history of hematological conditions. On physical examination, tenderness of right lower quadrant was noted. She was afebrile. Results of laboratory studies were unremarkable except for mildly elevated white blood cell count of 12,300 cells/mm<sup>3</sup>. She underwent computed tomography to rule out appendicitis which revealed right ovarian vein thrombosis. (Figure 1) shows axial section with arrow pointing to thrombosed vein, (Figure 2) shows coronal section. Hypercoagulable work up was negative. She has no known risk factors for thromboembolism and can be termed as idiopathic ovarian vein thrombosis. She is currently on anticoagulation. To date, only nine cases of idiopathic ovarian vein thrombosis have been reported.

**\*Corresponding author:** Namratha Kodali, Department of Internal Medicine, Pinnacle Health Hospital, Harrisburg, Pennsylvania, United States, Email: [kodalnamratha.k@gmail.com](mailto:kodalnamratha.k@gmail.com)

**Citation:** Kodali N, Lu K (2016) Idiopathic Ovarian Vein Thrombosis in a Healthy Individual. *Int J Clin Med Imaging* 3: 485. doi:[10.4172/2376-0249.1000485](https://doi.org/10.4172/2376-0249.1000485)

**Copyright:** © 2016 Kodali N. This is an open-access article distributed under the terms of the Creative Commons Attribution License, which permits unrestricted use, distribution, and reproduction in any medium, provided the original author and source are credited.